

Pulmonary embolism and thrombocytopenia following ChAdOx1 vaccination



Viktoria Muster, Thomas Gary, Reinhard B Raggam, Albert Wölfler, Marianne Brodmann

A 51-year-old woman attended our emergency department with a 3-day history of dyspnoea, fatigue, and cough; 11 days earlier she had the ChAdOx1 nCoV-19 vaccination. On examination she was afebrile, her peripheral oxygen saturation was 98% (fraction of inspired O₂ 21%), blood pressure was 150/90 mm Hg, heart rate was 98 beats per min, and body-mass index was 31 kg/m².

Laboratory investigations showed a severe thrombocytopenia of 37×10⁹ platelets per L; 3 days earlier it had been 178×10⁹ per L (normal 140–440). Serum concentrations of D-dimer (>34 mg/dL; normal <0.5) and C-reactive protein were increased (42 mg/L; normal <0.5); prothrombin time, partial thromboplastin time, fibrinogen, creatinine, electrolytes, aspartate aminotransferase, alanine aminotransferase, and high-sensitivity troponin T were within normal range. SARS-CoV-2 RT-PCR on a nasopharyngeal swab was negative.

CT pulmonary angiography showed a central pulmonary embolism without right ventricular dysfunction (figure). Magnetic resonance venography showed venous thrombus formation in the left internal iliac vein—including the common iliac vein—with extension into the inferior vena cava (figure; appendix).

We started low-molecular weight heparin (LMWH) at half the therapeutic dose. The patient was admitted and empirically treated with dexamethasone 40 mg orally—we assumed an autoimmune process was responsible for the rapid platelet reduction. Other causes of thrombocytopenia were excluded (appendix).

After 3 days of glucocorticoid therapy, the patient's platelet concentration remained low and the fibrinogen levels dropped rapidly to below 50 mg/dL; factor XIII also dropped to 32% activity (normal >70%); the prothrombin time became unmeasurable. Plasma coagulation factor activities were normal for all other extrinsic and intrinsic coagulation factors—including von Willebrand factor.

Mixing the patient's plasma in a 1:1 ratio with standard human plasma showed a deficiency of fibrinogen and factor XIII; thrombelastography confirmed the result (for details see appendix).

LMWH was increased to a therapeutic dose leading to an anti-factor Xa activity of 0.5–1.0 IU/mL (therapeutic range 0.5–1.0).

On day 5, the patient developed pain in the left lower back and left gluteal region; CT venography showed an increase in the thrombus in the inferior vena cava. The LMWH dose was increased to obtain supratherapeutic anti-factor Xa activity (1.0–1.5 U/mL). On the following day, the pain had reduced.

Over the next 7 days, the platelet count and factor XIII activity increased; fibrinogen levels also started to increase

after the platelet count reached 100×10⁹ per L. 11 days after admission the platelet count was 173×10⁹ per L, fibrinogen concentration was 228 mg/L, and factor XIII activity was 78% (appendix). Anticoagulation therapy was switched from LMWH to oral dabigatran 150 mg twice a day and on day 15 the patient was well and allowed home.

Activation of the coagulation system producing thromboses in the context of thrombocytopenia and hypofibrinogenaemia—as occurred in our patient—is similar to heparin-induced thrombocytopenia and to that seen in critically ill COVID-19 patients (video).

Contributors

We were all involved in treating the patient, and drafting, reviewing, and writing the final manuscript. Written consent for publication was obtained from the patient.

Declaration of interests

We declare no competing interests.

Acknowledgments

We are indebted to Johannes Schmid, Michael Fuchsjaeger, Manuela Aschauer, and Hannes Deutschmann, Department of Radiology, Medical University of Graz, for support with the CT and magnetic resonance images.

© 2021 Elsevier Ltd. All rights reserved.

Published Online
April 14, 2021
[https://doi.org/10.1016/S0140-6736\(21\)00871-0](https://doi.org/10.1016/S0140-6736(21)00871-0)

Division of Angiology (V Muster MD, T Gary MD, R B Raggam MD, M Brodmann MD) and Department of Haematology (A Wölfler MD), Department of Internal Medicine, Medical University of Graz, Graz, Austria

Correspondence to: Dr Thomas Gary, Division of Angiology, Department of Internal Medicine, Medical University Graz, Graz 8036, Austria
thomas.gary@medunigraz.at

See Online for video

See Online for appendix

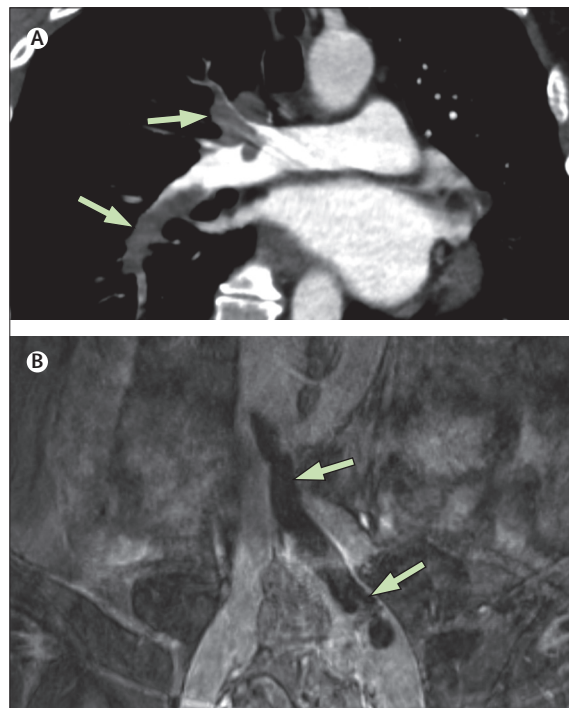


Figure: Thromboses and thrombocytopenia after ChAdOx1 nCoV-19 vaccination. CT pulmonary angiography shows a central pulmonary embolism (arrows; A). Magnetic resonance venography shows a venous thrombus in the left internal iliac vein—including the common iliac vein—with extension into the inferior vena cava (arrows; B).