

REVIEW ARTICLE

Dan L. Longo, M.D., *Editor*

Hematuria in Adults

Julie R. Ingelfinger, M.D.

VISIBLE (MACROSCOPIC) HEMATURIA, DOCUMENTED SINCE ANCIENT times,^{1,2} is striking, particularly when there is no prior event, such as trauma, dysuria due to cystitis, or flank pain with passage of a kidney stone, to provide a clear explanation. In contrast, nonvisible (microscopic) hematuria, or microhematuria, may go undetected for years.² Many patients are found to have microhematuria when a urinalysis is performed for other reasons.

The reported prevalence of microhematuria varies greatly, from a small percentage of patients at screening to more than 40% in some urology clinics, probably owing to referral bias regarding patients and their signs and symptoms.³⁻⁵ The American Urological Association (AUA) guidelines note a prevalence ranging from 2.1 to 31.4%.⁵ Thus, a discussion of epidemiology per se is less important than a consideration of individual patient circumstances and geographic region. In certain parts of the world — for example, in northern Africa, where *Schistosoma haematobium* is endemic — microhematuria is common, reflecting prevalent bladder infestation.

In addition, the causes of hematuria differ between men and women, and the evaluation, accordingly, should reflect that difference.⁶⁻⁸ Furthermore, the implications of hematuria vary greatly, depending on the underlying cause. Given the association of both visible hematuria and microhematuria with bladder and kidney cancer, the focus of evaluation has long been to rule out cancer. Cancer is more likely to be identified in men than in women when they are evaluated for microhematuria. Worldwide, estimates of the incidence of kidney cancer are 6.0 cases per 100,000 person-years for men and 3.1 cases per 100,000 person-years for women, and estimates of the incidence of bladder cancer are 9.0 cases per 100,000 person-years for men and 2.2 cases per 100,000 person-years for women, according to GLOBOCAN, a registry of data on the global incidence of cancer,⁹ a result also found in a 2020 meta-analysis.¹⁰ However, evaluation in women is often delayed, which may contribute to worse outcomes of bladder cancer among women.

Beyond cancer, hematuria is associated with protean symptoms and causes. This review focuses on major causes, the evaluation, and the implications of hematuria. Since therapy depends on the cause, treatment is not addressed here.

DETECTION OF HEMATURIA

Urine hue normally ranges from nearly colorless, when dilute, to dark amber, when concentrated. Red, pink, “rusty,” or brown urine may suggest hematuria but may be due to substances besides blood. Available dipstick tests detect red cells, as well as hemoglobin and myoglobin, necessitating microscopic examination of the urine if a dipstick test is heme-positive, followed by other tests to confirm hematuria and, potentially, to determine its cause.^{11,12}

Commonly used dipstick tests incorporate a benzidine compound reduced with a buffered organic peroxide (3,3',5,5'-tetramethylbenzidine and diisopropylbenzene dihydroperoxide). When the test strip is dipped in urine that includes an oxidizing substrate, a color reaction ensues; for example, the pseudoperoxidase

N Engl J Med 2021;385:153-63.

DOI: 10.1056/NEJMra1604481

Copyright © 2021 Massachusetts Medical Society.

Table 1. Selected Nonheme Causes of Pigmenturia, as Compared with Red Cells or Free Hemoglobin.*

Variable	Red Cells	Hemoglobin	Myoglobin	Porphyria	Bile Pigments	Alkaptonuria
Urine color	Red to rusty	Pink to red	Rusty	Turns black, brown, or red in sunlight	Brown	Turns dark in sunlight
Heme test	Positive	Positive	Positive	Negative	Negative	Negative
Usual microscopic findings	Red cells, casts	No cells	No red cells; casts may be present	Normal	Normal	Normal
Plasma	Normal	Pink	Normal	Normal	Icteric	Normal

* Shown are selected endogenous causes of pigmenturia. A heme test for exogenous causes, including beets, rhubarb, azo dye, sulfonamides, and phenolphthalein, is negative.

activity of hemoglobin will oxidize the benzidine compound, turning the dipstick blue. Free hemoglobin and myoglobin also react with the test strip, as would be expected because of their molecular structure.¹³

Certain substances may lead to false positive dipstick reactions: sodium hypochlorite, peroxidases from vegetable or bacterial sources, and semen. In contrast, very high ascorbic acid levels in urine may produce false negative results. The list of substances that can be confused with hematuria is lengthy (see the partial listing in Table 1). The absence of red cells on microscopic examination of a “heme-positive” urine specimen suggests either that the red cells have all lysed or that isolated hemoglobinuria or myoglobinuria may be present. Hemoglobinuria is dipstick-positive, but if it is the sole cause of the positive test, red cells will not be present in the urinary sediment. In some instances, both hematuria and hemoglobinuria are present and red cells will be identified.

Distinguishing blood from myoglobin in the urine (which may signify rhabdomyolysis and may or may not be suspected, given a patient’s history) is clinically important.¹⁴ Frequently, centrifugation is helpful, since red cells will sediment, leaving a clear supernatant, whereas myoglobin will not. However, free hemoglobin also will not precipitate in a routine laboratory centrifuge. In all, the absence of red cells in the sediment of a “heme-positive” specimen suggests that either isolated hemoglobinuria or myoglobinuria may be present. Myoglobinuria can then be identified biochemically through ammonium sulfate precipitation, as well as through electrophoretic and immunologic tests.

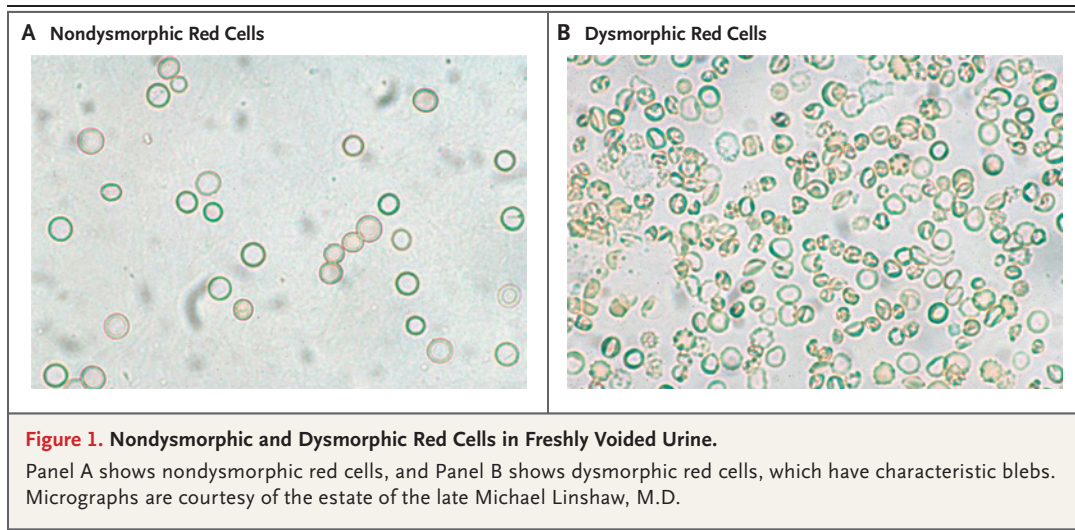
Thus, after a positive dipstick test, microscopic examination of the urinary sediment is

essential.¹⁵ True microhematuria is most often defined as more than 2 or 3 red cells per high-power field, and this finding should be confirmed on two or three separate urinalyses.^{16,17} Some experts suggest that if even a single urinalysis is positive, a patient should have follow-up urinalyses for at least a year, so as to avoid missing an intermittent source of microhematuria that could signify a clinically important problem.

Careful examination of the urinary sediment is central to differentiating glomerular from other forms of hematuria.¹⁵ Although micrographs of red cells crossing the glomerular basement membranes are as rare as hen’s teeth, red cells that have traversed the glomerular basement membrane into the glomerular filtrate are much the worse for wear and appear with blebs and other irregularities.¹⁸ In contrast, lower urinary tract hematuria is characterized by normal red cells (Fig. 1). If dysmorphic red cells are found, the diagnostic evaluation should first focus on the possibility of a glomerulopathy (see the pragmatic algorithm in Fig. 2), particularly if casts, especially red-cell casts, are present.

Isolated hematuria is less likely to be associated with a glomerulopathy than is hematuria with albuminuria or decreased kidney function, though IgA nephropathy and familial nephropathies may not always be characterized by albuminuria.¹⁵ Bacteria in the unspun urine and in the sediment suggests urinary tract infection. Crystals may suggest nephrolithiasis.

If examination of the urinary sediment shows normal-appearing red cells, then imaging and urologic referral should be considered. Most urologists will focus on imaging results and cystoscopy. In patients with risk factors for cancer, many urologists and guidelines would suggest



either urethrocytostcopy and computed tomographic (CT) urography¹⁹ or ultrasonography and cystoscopy.⁵

Glomerular hematuria in the absence of proteinuria or kidney dysfunction has largely been considered to be an innocuous finding or perhaps a marker of changes in the glomerular filtration apparatus or of inflammation, yet some data suggest that isolated glomerular hematuria may not always be innocuous.²⁰ Over time, even in conditions considered to have a good prognosis, microhematuria has been associated with progressive kidney failure, and macrohematuria has been associated with acute tubular dysfunction and acute kidney injury.²⁰ For instance, episodes of gross hematuria in persons with IgA nephropathy may be accompanied by diminution of the glomerular filtration rate or frank acute kidney injury, but the patient generally recovers.²¹ Vivante et al.²² reported that microhematuria among army recruits was associated with a risk of end-stage kidney disease many years later. Furthermore, kidney donors who have had microhematuria have been reported to have an increased risk of kidney dysfunction after donation.²³

The mechanism of kidney injury may be due to the effects of tubular inflammation and oxidative stress induced by breakdown products of red cells.^{24,25} Whether glomerular hematuria itself induces progression or is a surrogate for inflammation is unclear. Moreno et al.^{24,25} postulate that red-cell casts induce damage to tubular cells through obstruction, that hemoglobin and heme are directly toxic to the tubules, and that

renal tubular cells subsequently engage in erythrophagocytosis, which has been linked to further nephrotoxicity induced by iron and hemoglobin.²⁶

CONFIRMED VISIBLE HEMATURIA

Visible hematuria often has an obvious explanation, which is congruent with the patient's history, signs, and symptoms (e.g., the passage of a kidney stone, acute hemorrhagic cystitis, or a sickle-cell crisis). However, many other conditions can cause visible hematuria (Fig. 3). Thus, the evaluation of gross hematuria should be focused on the basis of the patient's symptoms and concomitant clinical and laboratory findings.²⁷ In adults over the age of 40 years (some sources suggest a cutoff age of 35 years), an unexplained episode of visible hematuria may signify bladder or upper urinary tract cancer, and most experts suggest urologic referral along with imaging and cystoscopy to rule out cancer.²⁸⁻³¹

MEDICAL HISTORY AND PHYSICAL EXAMINATION

A thorough history is critical in focusing the diagnostic evaluation of a patient with gross hematuria.²⁷⁻³¹ Has the patient had trauma, and might there be a renal contusion, vascular compromise, or infarction? A history suggestive of urinary tract infection or renal colic calls for an initial evaluation to confirm or rule out an infection or a kidney stone. If the patient has just undergone surgery, is there a complication, even if the surgical procedure did not directly involve

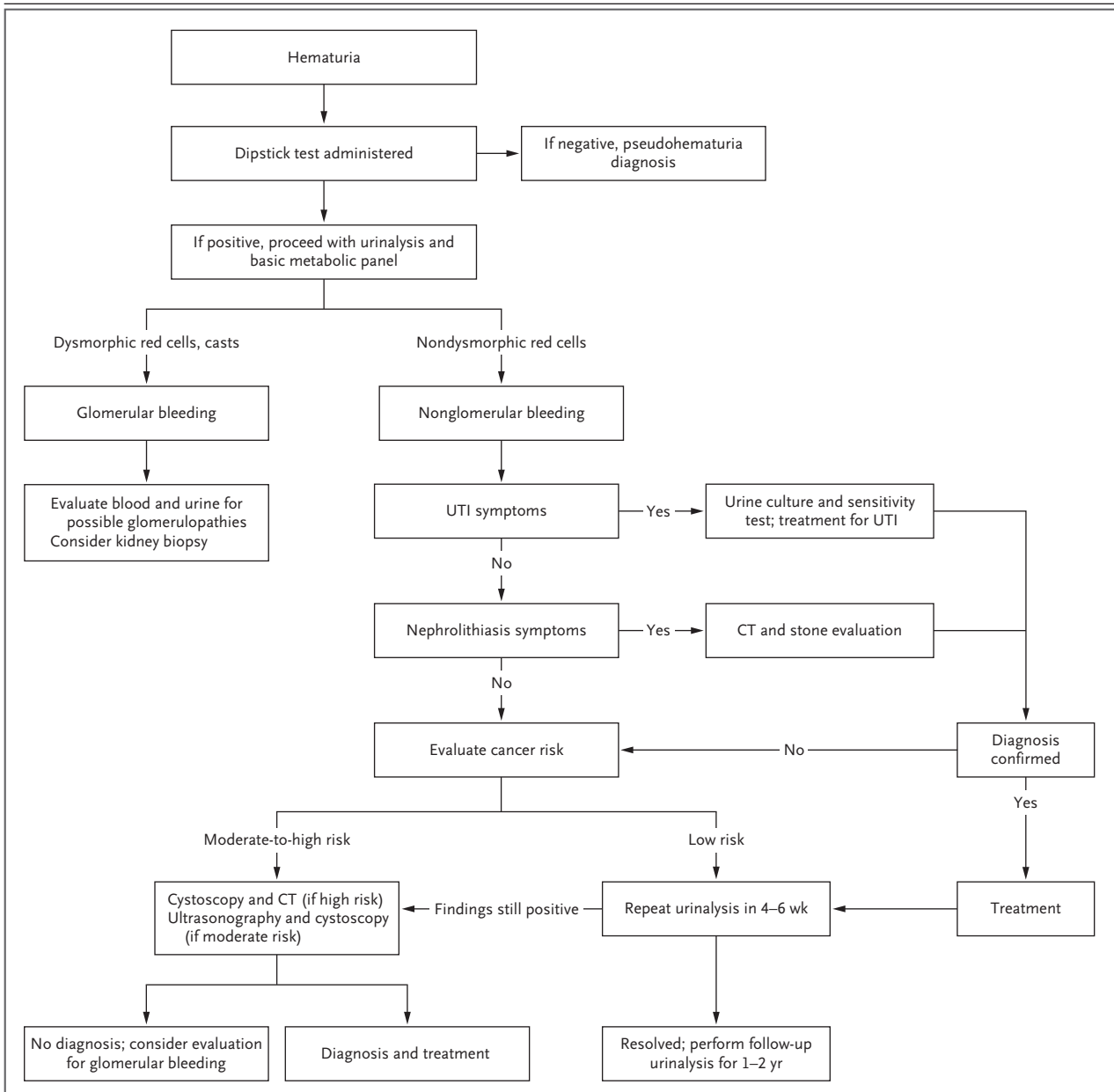


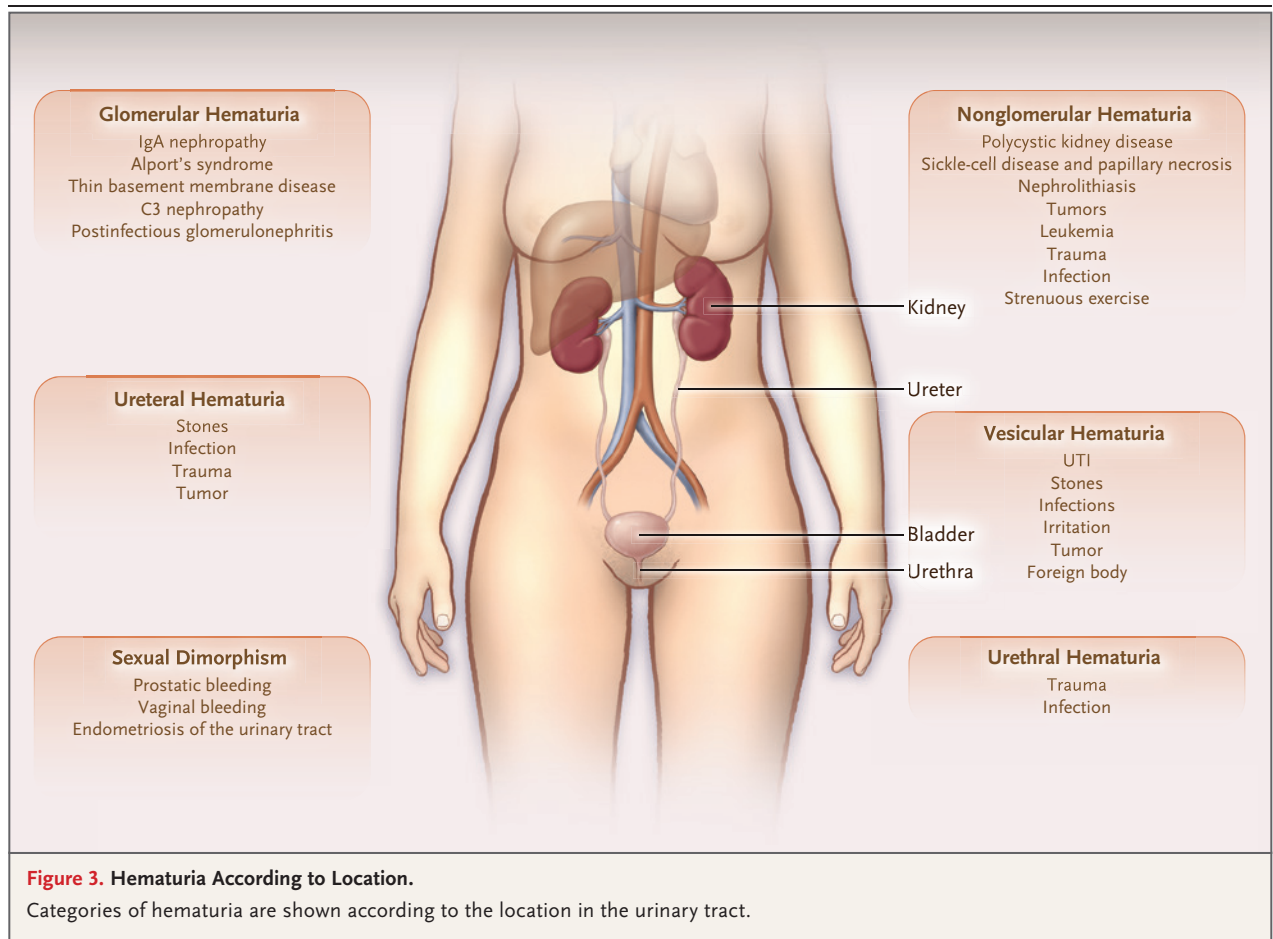
Figure 2. Algorithm Incorporating Risk Assessment in the Evaluation of Hematuria.

The algorithm is based on the current American Urological Association guidelines. UTI denotes urinary tract infection.

the kidneys? Is the patient receiving anticoagulants? Has the patient engaged in strenuous activity, such as a long-distance run, which may occasionally be associated with visible hematuria? Has the patient's voiding pattern changed, which could be suggestive of prostatic hypertrophy or obstruction? Does the patient have flank pain or suprapubic pain?

The physical examination further focuses the

workup.²⁷⁻³¹ Are vital signs stable, and is there any sign of vascular instability that would suggest bleeding or some other acute, potentially life-threatening problem? Costovertebral angle or suprapubic tenderness may suggest a kidney stone or a urinary tract infection. In male patients, rectal examination to palpate the prostate may help assess the possibility of prostatitis or prostate cancer. In female patients, it is impor-



tant to be sure that the bleeding is from the urinary tract, not the reproductive tract. Signs of systemic disease should also be sought.

IMAGING

Imaging is generally considered necessary in adults with gross hematuria, given the possibility of cancer, unless there is an obvious cause (e.g., hemorrhagic cystitis). For many patients, ultrasonography plus cystoscopy suffices. CT urography is recommended by some sources but is more costly than ultrasonography and usually includes the administration of contrast material.²⁷⁻³¹ The use of magnetic resonance imaging is not generally recommended. It is said that dysuria is present in approximately 80% of patients with bladder cancer and that dysuria doubles the likelihood of finding a bladder cancer.³²

In DETECT 1, a prospective, observational study involving 3556 adults (59% were men, with

a mean age of 65.7 years) with visible or microscopic hematuria, 10% of the cohort had cancers, mainly bladder cancer (in 8.0% of all patients evaluated); cancer was more common among those with visible hematuria.³³ Renal parenchymal cancer was seen in 1.0% of the patients, upper tract transitional-cell cancer in 0.7%, and prostate cancer in 0.3%. In this study, cancer was most likely to be diagnosed in the male patients, especially older men and men with a history of smoking. The results of most trials, taken together, have suggested that any patient with visible blood in the urine should undergo urologic investigation.^{5,33}

CONFIRMED MICROHEMATURIA

The most common causes of microhematuria are nonmalignant⁵: glomerulopathies (e.g., IgA nephropathy or thin glomerular basement membrane disease) and inflammatory conditions of

the urethra, prostate, and bladder, as well as renal calculi and benign prostatic hypertrophy. The causes of microhematuria are many and disparate, as summarized in Figure 3.

Most sources state that confirmed microhematuria requires evaluation, since overlooking a bladder cancer or kidney cancer would be potentially fatal, but that viewpoint has been challenged in recent years.^{34,35} Urinary tract cancer is rare in women, and recent data suggest that the likelihood of cancer is less than 5% in a woman under 50 years of age who has never smoked and who has asymptomatic microhematuria with fewer than 25 red cells per high-power field.⁸ Even for men, some guidelines suggest individualized evaluation. Such recommendations note that evaluation of microhematuria is time-consuming and costly and may cause more harm than good. In one study, up to 57% of patients referred to a urology service for microhematuria turned out to have pseudohematuria.¹² Given all these considerations, the decision to evaluate a patient may best be based on a mutual decision arrived at through discussion between patient and clinician.

There is debate about whether evaluation of microhematuria should include invasive testing such as cystoscopy, even though the annual incidence of urinary tract cancers is substantial. For example, in 2009, an estimated 70,980 bladder cancers and 57,760 renal cancers were diagnosed in the United States. In 2020, the estimated numbers of new bladder and renal cancer cases were 81,400 and 73,750, respectively, according to the American Cancer Society.³⁶

Although, as noted above, most patients with urinary tract cancer present with hematuria, asymptomatic microhematuria has a consistently poor performance as a trigger for diagnostic investigations. For example, Jung et al.³⁷ examined the medical records of 156,692 patients with microhematuria; the incidence of urinary tract cancer was 0.7% over a period of 3 years.³⁷ An age of more than 40 years, the presence of more than 25 red cells per high-power field, and male sex increase the risk of cancer. Additional risk factors include occupational exposure to carcinogens, particularly aromatic amines and hydrocarbons (involved in chimney maintenance and dye work); analgesic abuse; pelvic irradiation; chemotherapy courses involving alkylating

agents (e.g., cyclophosphamide); and prolonged exposure to foreign bodies (e.g., catheters).

In the above-mentioned DETECT 1 trial,³³ 10% of patients had malignant tumors, the majority of which were bladder cancers. In another study, 234 male patients who had had a negative evaluation for microhematuria were followed for 14 years; urinary tract cancer developed in 2 of these patients (0.9%).³⁸

Despite the low frequency of urinary tract cancer, expert opinion favors evaluation.^{5,39-42} Nielsen and Qaseem, for example, recommend that if a patient has persistent microhematuria, evaluation should proceed, even if that patient is receiving antiplatelet or anticoagulant medication.³⁹ In contrast, the 2012 AUA guidelines, based on a review of 191 evidence-based reports and on expert opinion for areas and concepts lacking such data, recommended evaluation for all patients 35 years of age or younger in whom microhematuria does not have an obvious, identified benign cause, according to the history, physical examination, and urinalysis.⁴² That workup, according to the AUA, should include cystoscopy and upper urinary tract imaging with CT.

MEDICAL HISTORY

As with visible hematuria, it is crucial to obtain a good history in order to focus the evaluation of microhematuria.^{5,15} Is the patient symptomatic, and if so, what are those symptoms?

The evaluation of microhematuria is focused on ruling out diagnoses that are very important not to miss — mainly, urinary tract cancers. Microhematuria is detected by dipstick testing or examination of the urinary sediment. It is important to ascertain that the patient does not have a urinary tract infection, is not menstruating, and has not just exercised, engaged in sexual activity, or had exposure to instrumentation (e.g., through cystoscopy).

A careful examination of the urinary sediment is key. It is best to obtain a clean-catch mid-stream urine sample — ideally, the first void of the day — and examine it within 1 to 2 hours. The first void of the day has higher osmolality and lower pH (both of which are helpful in preserving the morphologic features of formed sediment elements) than a sample obtained later in the day.⁵ There are standard ways to perform a urinalysis, generally spinning the sample at

4000 rpm for 5 minutes after obtaining a dipstick reading.^{11,15} The normal number of red cells in the urinary sediment is generally agreed to be fewer than 2 or 3 per high-power field.^{5,11,15} The presence of red cells in one urinalysis should be confirmed in one or two more urinalyses. If microhematuria is not confirmed in a second or third urinalysis, many sources suggest repeated testing over a period of a year or so. If microhematuria is confirmed, then it is important next to consider whether the findings suggest an upper or a lower urinary tract origin.

The morphologic characteristics of red cells,⁴³⁻⁴⁷ as well as a review of dipstick results, the formed elements in the urinary sediment, and any other urinary abnormalities detected, may suggest whether upper or lower urinary tract bleeding is more likely, with dysmorphic red cells in the sediment suggesting an upper urinary tract (glomerular) source of bleeding.⁵ According to some sources, a finding that more than 25% of urinary red cells are dysmorphic points to glomerular disease.⁴⁷ Urinary red-cell mean corpuscular volume has also been used to help differentiate between upper and lower urinary tract disease.⁴⁸ The sensitivity of both dysmorphic and small red-cell findings has been challenged. The presence of proteinuria should impel the clinician to launch an investigation for a major nephropathy.¹⁵ In sum, isolated hematuria with dysmorphic red cells or red cells with a decreased mean corpuscular volume, with or without casts, should prompt an evaluation for glomerulopathy as well. The most commonly associated glomerulopathies are IgA nephropathy and Alport's syndrome (familial nephritis). But the list of potential glomerulopathies is long, and an evaluation of kidney function, complement status, and autoimmune markers is indicated, depending on the individual patient. Even if the blood in the urine appears to be due to lower urinary tract disease, kidney function and the estimated glomerular filtration rate should be checked. The specific studies will depend on the possibilities that seem likely (Fig. 2).

CYTOLOGIC ANALYSIS

Urinary cytologic analysis⁴⁹⁻⁵² has long been recommended as a possible adjunct to cystoscopy and can serve as a way to find evidence of small carcinomas that are overlooked on cystoscopy.

In a study by Mishriki et al.,⁴⁹ in which 2278 patients underwent urinary cytologic analysis, only 2 were determined to have cancer on the basis of the cytologic findings. Cytologic analysis in a study by Hofland et al.⁵⁰ showed cancer in 4 of 1000 urine samples, and in 2 of those 4 samples, cancer was detected only on the basis of cytologic findings. Current practice is to limit the use of cytologic analysis to cases of gross hematuria or symptomatic hematuria.^{5,52}

IMAGING

Adults with established microhematuria should undergo imaging, and as with visible hematuria, the most cost-effective combination of studies has been found to be ultrasonography plus cystoscopy.⁵ Using decision analysis, Halpern et al.³⁴ looked at simulated cancer detection rates in persons with asymptomatic microhematuria and associated costs in terms of the incremental costs of cancer detection. They examined four imaging approaches: CT urography alone, cystoscopy alone, CT urography plus cystoscopy, and ultrasonography plus cystoscopy. Ultrasonography plus cystoscopy detected the most cancers per incremental cost of cancer detection, and exchanging CT urography for ultrasonography would have detected only one additional cancer.

CYSTOSCOPY

For patients who have gross hematuria without an obvious cause, cystoscopy is generally recommended in order to rule out cancer, most often bladder cancer. The 2012 AUA guidelines⁴² recommended cystoscopy for all patients with microhematuria who are older than 35 years of age, but the 2020 AUA guidelines⁵ added risk levels and recommended immediate cystoscopy only for patients at increased risk.

MOLECULAR BIOMARKERS

The possibility that molecular markers might focus the workup of hematuria is attractive.⁵³ Biomarkers for various urinary tract cancers,^{54,55} for glomerular disease,^{56,57} and for genetic diseases⁵⁸ are of great interest. Bladder cancer is heterogeneous, and if there were prospectively validated markers, they might serve as important adjuncts in clinical decision making.⁵³ Whereas 90 to 95% of bladder cancers are urothelial

(transitional-cell) carcinomas, only 3 to 7% are squamous-cell carcinomas (usually in the renal pelvis and ureters), and less than 3% are adenocarcinomas (most often in the trigonal region). The relevant markers for distinct types of cancer appear to differ. Sathianathan et al.⁵⁴ carried out a meta-analysis in which 17 studies met the specified criteria. The authors found substantial heterogeneity among the studies. Evaluating several biomarkers in combination (NMP22, UroVysion, and uCyt+) or alone (bladder tumor-associated antigen [BTA], NMP22, uCyt+, Cxbladder, and AssureMDx), they calculated that the biomarkers had high sensitivity but insufficient specificity to eliminate the need for cystoscopy. Wilson et al.⁵⁵ noted that BTA and NMP22, which are approved by the Food and Drug Administration for use together with cystoscopy for the diagnosis of bladder cancer, do not work well if used alone, since hematuria in the absence of cancer, as well as infections and stones, is associated with false positive test results. To date, despite the interest in biomarkers, the types of prospective studies needed to render biomarkers clinically useful are lacking.

Nucleic acids detected in plasma, including DNA (genomic, as well as mitochondrial and viral), RNA, and microRNA, have been recognized for some time as potential biomarkers. Circulating tumor DNAs (ctDNAs) are used as biomarkers in multiple areas of oncology. The detection of ctDNA in muscle-invasive bladder cancer is being piloted for use in diagnosis and for monitoring during treatment and follow-up care.⁵⁹ Cell-free DNA has been used similarly in renal-cell carcinoma.⁶⁰

MICROHEMATURIA WITH NO IDENTIFIED CAUSE

The specific cause of hematuria may be elusive. In some series, more than half of the patients have microhematuria with no definable cause. Bolenz et al.³² suggest a “risk-adapted investigation,” connoting a personalized and risk–benefit approach to evaluation that is based on the view that every patient with hematuria should be evaluated, but not every possible test should be used. Furthermore, if no cause is identified, at a certain point, it makes sense to live with uncertainty. Follow-up of the patient with microhematuria depends on the history and evaluation. In

the absence of a specific diagnosis, monitoring at intervals is considered to be important — initially after an interval of a few months and then once or twice yearly.

GUIDANCE FOR SCREENING AND EVALUATION

Given the wide differential diagnosis and the disparate reports about the import of microhematuria, current guidance varies. The American College of Physicians has stated (in 2016)³⁹ that asymptomatic adults as a group should not be screened by means of urinalysis for cancer detection and that for those who are nonetheless screened and found to have a positive dipstick test, the presence of blood should be confirmed by microscopic urinalysis. The U.S. Preventive Services Task Force does not recommend screening for microhematuria, citing inadequate evidence of benefit versus harm.⁶¹ Others have also considered the issue of harms and benefits.^{62,63}

Table 2. Risk Stratification for Bladder Cancer.

Low risk (all criteria must be met)

<40 Yr of age for men, <50 yr of age for women
Never smoked or <10 pack-yr of smoking
3–10 Red cells per high-power field on one urinalysis
No risk factors for urothelial cancer

Intermediate risk (one criterion raises the risk to intermediate)

40–59 Yr of age for men and women
10–30 Pack-yr of smoking
11–25 Red cells per high-power field on repeat urinalysis
Additional risk factors for urothelial cancer

High risk (one criterion raises the risk to high)

≥60 Yr of age for men and women
>30 Pack-yr of smoking
>25 Red cells per high-power field on single urinalysis
History of gross hematuria

Additional risk factors for urothelial cancer

Irritative lower urinary tract symptoms
Previous pelvic radiation therapy
Previous chemotherapy with cyclophosphamide or ifosfamide
Family history of urothelial cancer or Lynch syndrome
Occupational exposure to benzene or aromatic amines
Chronic indwelling foreign body in the urinary tract

In a 2018 review of guidelines and guidance¹⁹ on microhematuria, the lack of consensus on several points was clear. However, most of the guidelines state that the presence of 3 or more red cells in one, two, or three urinalyses justifies the diagnosis of microhematuria, whereas the Japanese Urological Association requires 5 or more red cells. Some other guidelines require a positive dipstick test.

Tan et al. recently developed a Haematuria Cancer Risk Score (HCRS)⁶⁴ to aid clinicians in considering evaluation. Using the DETECT 1 cohort, the investigators created a test cohort of 3539 patients in 40 hospitals in the United Kingdom (ClinicalTrials.gov number, NCT02676180) and a Swiss validation cohort of 656 persons. Use of the HCRS score, which is based on the patient's age and sex, type of hematuria, and smoking history, appeared to detect more cancers than were found by following the United Kingdom's National Institute for Health and Care Excellence (NICE) guidelines⁶⁵ or the AUA guidelines.⁵ There is also another risk score, which is not in general use.⁶⁶

The AUA guidelines were updated in 2020,⁵ through a panel created 2 years earlier by AUA Education and Research (AUAER) and the Soci-

ety of Urodynamics, Female Pelvic Medicine and Urogenital Reconstruction. The assessment now favored is based on risk categories (Table 2). The current guidelines comprise recommendations that are intended to control costs and limit risks associated with "overevaluation" of persons with a low likelihood of having urinary tract cancer while avoiding "underevaluation" of persons at high risk. Not surprisingly, the guidelines suggest a shared decision-making plan between patient and clinician. Many other guidelines and guidance documents⁶⁷⁻⁷² are available, and they agree about the importance of not missing a urinary tract cancer.

SUMMARY

Hematuria is an important sign that may connote serious disease, yet on many occasions no specific cause is identified. A high index of suspicion and good communication between clinician and patient can result in a reasoned and reasonable approach to evaluation and therapy.

No potential conflict of interest relevant to this article was reported.

Disclosure forms provided by the author are available with the full text of this article at NEJM.org.

REFERENCES

- Shokeir AA, Hussein MI. The urology of Pharaonic Egypt. *BJU Int* 1999;84:755-61.
- Armstrong JA. Urinalysis in Western culture: a brief history. *Kidney Int* 2007; 71:384-7.
- Mohr DN, Offord KP, Owen RA, Melton LJ III. Asymptomatic microhematuria and urologic disease. A population-based study. *JAMA* 1986;256:224-9.
- Woolhandler S, Pels RJ, Bor DH, Himmelstein DU, Lawrence RS. Dipstick urinalysis screening of asymptomatic adults for urinary tract disorders. I. Hematuria and proteinuria. *JAMA* 1989;262:1214-9.
- Barocas DA, Boorjian SA, Alvarez RD, et al. Microhematuria: AUA/SUFU Guideline. *J Urol* 2020;204:778-86.
- Ark JT, Alvarez JR, Koyama T, et al. Variation in the diagnostic evaluation among persons with hematuria: influence of gender, race and risk factors for bladder cancer. *J Urol* 2017;198:1033-8.
- Cohn JA, Vekhter B, Lyttle C, Steinberg GD, Large MC. Sex disparities in diagnosis of bladder cancer after initial presentation with hematuria: a nationwide claims-based investigation. *Cancer* 2014;120:555-61.
- Rabinowitz DE, Buford K, Wood AM, et al. Incidence of significant findings of microhematuria workup in women—what guidelines work best? *Urology* 2021;151: 19-23.
- Ferlay J, Soerjomataram I, Dikshit R, et al. Cancer incidence and mortality worldwide: sources, methods and major patterns in GLOBOCAN 2012. *Int J Cancer* 2015;136(5):E359-E386.
- Jubber I, Shariat SF, Conroy S, et al. Non-visible haematuria for the detection of bladder, upper tract, and kidney cancer: an updated systematic review and meta-analysis. *Eur Urol* 2020;77:583-98.
- Simerville JA, Maxted WC, Pahira JJ. Urinalysis: a comprehensive review. *Am Fam Physician* 2005;71:1153-62.
- Rao PK, Gao T, Pohl M, Jones JS. Dipstick pseudo-hematuria: unnecessary consultation and evaluation. *J Urol* 2010;183: 560-4.
- Litwin MS, Graham SD Jr. False-positive hematuria. *JAMA* 1985;254:1724.
- Adams EC. Differentiation of myoglobin and hemoglobin in biological fluids. *Ann Clin Lab Sci* 1980;10:493-9.
- Cohen RA, Brown RS. Microscopic hematuria. *N Engl J Med* 2003;348: 2330-8.
- Grossfeld GD, Litwin MS, Wolf JS, et al. Evaluation of asymptomatic microscopic hematuria in adults: the American Urological Association best practice policy — part I: definition, detection, prevalence, and etiology. *Urology* 2001;57:599-603.
- Sutton JM. Evaluation of hematuria in adults. *JAMA* 1990;263:2475-80.
- Makino H, Nishimura S, Soda K, Takaoka M, Kaneshige T, Ota Z. Mechanism of hematuria. I. Electron microscopic demonstration of the passage of a red blood cell through a glomerular capillary wall in rat masugi nephritis. *Virchows Arch B Cell Pathol Incl Mol Pathol* 1986; 50:199-208.
- Linder BJ, Bass EJ, Mostafid H, Boorjian SA. Guideline of guidelines: asymptomatic microscopic haematuria. *BJU Int* 2018;121:176-83.
- Yuste C, Gutierrez E, Sevillano AM,

- et al. Pathogenesis of glomerular haematuria. *World J Nephrol* 2015;4:185-95.
21. Praga M, Gutierrez-Millet V, Navas JJ, et al. Acute worsening of renal function during episodes of macroscopic hematuria in IgA nephropathy. *Kidney Int* 1985; 28:69-74.
 22. Vivante A, Afek A, Frenkel-Nir Y, et al. Persistent asymptomatic isolated microscopic hematuria in Israeli adolescents and young adults and risk for end-stage renal disease. *JAMA* 2011;306:729-36.
 23. Kido R, Shibagaki Y, Iwadoh K, et al. Persistent glomerular hematuria in living kidney donors confers a risk of progressive kidney disease in donors after heminephrectomy. *Am J Transplant* 2010;10: 1597-604.
 24. Moreno JA, Sevillano Á, Gutiérrez E, et al. Glomerular hematuria: cause or consequence of renal inflammation? *Int J Mol Sci* 2019;20:2205.
 25. Moreno JA, Martín-Cleary C, Gutiérrez E, et al. AKI associated with macroscopic glomerular hematuria: clinical and pathophysiologic consequences. *Clin J Am Soc Nephrol* 2012;7:175-84.
 26. Sheerin NS, Sacks SH, Fogazzi GB. In vitro erythrophagocytosis by renal tubular cells and tubular toxicity by haemoglobin and iron. *Nephrol Dial Transplant* 1999;14:1391-7.
 27. Willis GC, Tewelde SZ. The approach to the patient with hematuria. *Emerg Med Clin North Am* 2019;37:755-69.
 28. Mishriki SF, Vint R, Somani BK. Half of visible and half of recurrent visible hematuria cases have underlying pathology: prospective large cohort study with long-term followup. *J Urol* 2012;187:1561-5.
 29. Mishriki SF, Grimsley SJS, Nabi G. Incidence of recurrent frank hematuria and urological cancers: prospective 6.9 years of followup. *J Urol* 2009;182:1294-8.
 30. Expert Panel on Urological Imaging, Wolfman DJ, Marko J, et al. ACR Appropriateness Criteria® hematuria. *J Am Coll Radiol* 2020;17(5S):S138-S147.
 31. Wood DP Jr. Is it time to revise our evaluation of hematuria? *J Urol* 2009;182: 1253-4.
 32. Bolenz C, Schröppel B, Eisenhardt A, Schmitz-Dräger BJ, Grimm M-O. The investigation of hematuria. *Dtsch Arztebl Int* 2018;115:801-7.
 33. Tan WS, Feber A, Sarpong R, et al. Who should be investigated for haematuria? Results of a contemporary prospective observational study of 3556 patients. *Eur Urol* 2018;74:10-4.
 34. Halpern JA, Chughtai B, Ghomrawi H. Cost-effectiveness of common diagnostic approaches for evaluation of asymptomatic microscopic hematuria. *JAMA Intern Med* 2017;177:800-7.
 35. Subak LL, Grady D. Asymptomatic microscopic hematuria — rethinking the diagnostic algorithm. *JAMA Intern Med* 2017;177:808-9.
 36. American Cancer Society. Cancer statistics center ([https://cancerstatisticscenter.cancer.org/?_ga=2.82720342.1930708337.1595527626-1692772379.1595527626#/>](https://cancerstatisticscenter.cancer.org/?_ga=2.82720342.1930708337.1595527626-1692772379.1595527626#/)).
 37. Jung H, Gleason JM, Loo RK, Patel HS, Slezak JM, Jacobsen SJ. Association of hematuria on microscopic urinalysis and risk of urinary tract cancer. *J Urol* 2011; 185:1698-703.
 38. Madeb R, Golijanin D, Knopf J, et al. Long-term outcome of patients with a negative work-up for asymptomatic microhematuria. *Urology* 2010;75:20-5.
 39. Nielsen M, Qaseem A. Hematuria as a marker of occult urinary tract cancer: advice for high-value care from the American College of Physicians. *Ann Intern Med* 2016;164:488-97.
 40. Murakami S, Igarashi T, Hara S, Shimazaki J. Strategies for asymptomatic microscopic hematuria: a prospective study of 1,034 patients. *J Urol* 1990;144: 99-101.
 41. Khadra MH, Pickard RS, Charlton M, Powell PH, Neal DE. A prospective analysis of 1,930 patients with hematuria to evaluate current diagnostic practice. *J Urol* 2000;163:524-7.
 42. Davis R, Jones JS, Barocas DA, et al. Diagnosis, evaluation and follow-up of asymptomatic microhematuria (AMH) in adults: AUA guideline. *J Urol* 2012;188: 2473-81.
 43. Birch DF, Fairley KF. Haematuria: glomerular or non-glomerular? *Lancet* 1979; 2:845-6.
 44. Pollock C, Liu PL, Györy AZ, et al. Dismorphism of urinary red blood cells — value in diagnosis. *Kidney Int* 1989;36: 1045-9.
 45. Köhler H, Wandel E, Brunck B. Acanthocyturia — a characteristic marker for glomerular bleeding. *Kidney Int* 1991;40: 115-20.
 46. Kitamoto Y, Tomita M, Akamine M, et al. Differentiation of hematuria using a uniquely shaped red cell. *Nephron* 1993; 64:32-6.
 47. Hamadah AM, Gharaibeh K, Mara KC, et al. Urinalysis for the diagnosis of glomerulonephritis: role of dysmorphic red blood cells. *Nephrol Dial Transplant* 2018;33:1397-403.
 48. Shichiri M, Hosoda K, Nishio Y, et al. Red-cell-volume distribution curves in diagnosis of glomerular and non-glomerular haematuria. *Lancet* 1988;1:908-11.
 49. Mishriki SF, Aboumarzouk O, Vint R, Grimsley SJ, Lam T, Somani B. Routine urine cytology has no role in hematuria investigations. *J Urol* 2013;189:1255-8.
 50. Hofland CA, Mariani AJ. Is cytology required for a hematuria evaluation? *J Urol* 2004;171:324-6.
 51. Yafi FA, Brimo F, Auger M, Aprikian A, Tanguay S, Kassouf W. Is the performance of urinary cytology as high as reported historically? A contemporary analysis in the detection and surveillance of bladder cancer. *Urol Oncol* 2014;32(1): 27.e1-6.
 52. Kassouf W. The value of urine cytology in the workup of hematuria. *Cancer Cytopathol* 2016;124:303-4.
 53. Soria F, Krabbe L-M, Todenhöfer T, et al. Molecular markers in bladder cancer. *World J Urol* 2019;37:31-40.
 54. Sathianathen NJ, Butaney M, Weight CJ, Kumar R, Konety BR. Urinary biomarkers in the evaluation of primary hematuria: a systematic review and meta-analysis. *Bladder Cancer* 2018;4:353-63.
 55. Wilson JL Jr, Antoniassi MP, Lopes PI, Azevedo H. Proteomic research and diagnosis in bladder cancer: state of the art review. *Int Braz J Urol* 2021;47:503-14.
 56. Suzuki H. Biomarkers for IgA nephropathy on the basis of multi-hit pathogenesis. *Clin Exp Nephrol* 2019;23:26-31.
 57. Coppo R. Biomarkers and targeted new therapies for IgA nephropathy. *Pediatr Nephrol* 2017;32:725-31.
 58. Benonisdottir S, Kristjansson RP, Oddsson A, et al. Sequence variants associating with urinary biomarkers. *Hum Mol Genet* 2019;28:1199-211.
 59. Tan MP, Attard G, Huddart RA. Circulating tumour DNA in muscle-invasive bladder cancer. *Int J Mol Sci* 2018;19: 2568.
 60. Nuzzo PV, Berchuck JE, Korthauer K, et al. Detection of renal cell carcinoma using plasma and urine cell-free DNA methylomes. *Nat Med* 2020;26:1041-3.
 61. Moyer VA. Screening for bladder cancer: U.S. Preventive Services Task Force recommendation statement. *Ann Intern Med* 2011;155:246-51.
 62. Bauer SR, Carroll PR, Grady D. Hematuria practice guidelines that explicitly consider harms and costs. *JAMA Intern Med* 2019;179:1362-4.
 63. Georgieva MV, Wheeler SB, Erim D, et al. Comparison of the harms, advantages, and costs associated with alternative guidelines for the evaluation of hematuria. *JAMA Intern Med* 2019;179:1352-62.
 64. Tan WS, Ahmad A, Feber A, et al. Development and validation of a haematuria cancer risk score to identify patients at risk of harbouring cancer. *J Intern Med* 2019;285:436-45.
 65. Suspected cancer: recognition and referral. NICE guideline. London: National Institute for Health and Care Excellence, 2015 (<https://www.nice.org.uk/guidance/ng12/resources/suspected-cancer-recognition-and-referral-pdf-1837268071621>).
 66. Wu X, Lin J, Grossman HB, et al. Projecting individualized probabilities of developing bladder cancer in white indi-

- viduals. *J Clin Oncol* 2007;25:4974-81.
67. van der Molen AJ, Hovius MC. Hematuria: a problem-based imaging algorithm illustrating the recent Dutch guidelines on hematuria. *AJR Am J Roentgenol* 2012;198:1256-65.
68. Assmus MA, Beyer DB, Hanks J, et al. Quality and cost assessment of Canadian Urological Association microscopic hematuria guidelines in clinical practice: turning urine into gold. *Can Urol Assoc J* 2019;13:406-11.
69. Wollin T, Laroche B, Psooy K. Canadian guidelines for the management of asymptomatic microscopic hematuria in adults. *Can Urol Assoc J* 2009;3:77-80.
70. Anderson J, Fawcett D, Feehally J, Goldberg L, Kelly J, MacTier R. Joint consensus statement on the initial assessment of haematuria. July 2008 (https://www.baus.org.uk/_userfiles/pages/files/News/haematuria_consensus_guidelines_July_2008.pdf).
71. Woldu SL, Ng CK, Loo RK, et al. Evaluation of the new American Urological Association guidelines risk classification for hematuria. *J Urol* 2021;205:1387-93.
72. Skaggs AW, Loehfelm TW, Fananapazir G, Dall'Era M, Corwin MT. Utilization and yield of CT urography: are the American Urological Association guidelines for imaging of patients with asymptomatic microscopic hematuria being followed? *AJR Am J Roentgenol* 2021;216:106-10.

Copyright © 2021 Massachusetts Medical Society.

IMAGES IN CLINICAL MEDICINE

The *Journal* welcomes consideration of new submissions for Images in Clinical Medicine. Instructions for authors and procedures for submissions can be found on the *Journal's* website at NEJM.org. At the discretion of the editor, images that are accepted for publication may appear in the print version of the *Journal*, the electronic version, or both.