

# Interpretation of peripheral arterial and venous Doppler waveforms: A consensus statement from the Society for Vascular Medicine and Society for Vascular Ultrasound

Vascular Medicine  
2020, Vol. 25(5) 484–506  
© The Author(s) 2020  
Article reuse guidelines:  
sagepub.com/journals-permissions  
DOI: 10.1177/1358863X20937665  
journals.sagepub.com/home/vmj



Esther SH Kim<sup>1\*§</sup>, Aditya M Sharma<sup>2\*§§</sup>,  
Robert Scissons<sup>3\*\*§§</sup>, David Dawson<sup>4\*\*</sup>,  
Robert T Eberhardt<sup>5\*</sup>, Marie Gerhard-Herman<sup>6\*</sup>,  
Joseph P Hughes<sup>7\*\*</sup>, Steve Knight<sup>8\*\*</sup>, Ann Marie Kupinski<sup>9,10\*\*</sup>,  
Guillaume Mahe<sup>11\*</sup>, Marsha Neumyer<sup>12\*\*</sup>, Patricia Poe<sup>13\*\*</sup>,  
Rita Shugart<sup>14\*</sup>, Paul Wennberg<sup>15\*</sup>, David M Williams<sup>16\*\*</sup>,  
and R Eugene Zierler<sup>17\*</sup>

This document has been endorsed by the Society for Vascular Medicine and the Society for Vascular Ultrasound and is copublished in *Vascular Medicine* and the *Journal for Vascular Ultrasound*. The contributions are identical except for minor differences in keeping with each journal's style.

## Abstract

This expert consensus statement on the interpretation of peripheral arterial and venous spectral Doppler waveforms was jointly commissioned by the Society for Vascular Medicine (SVM) and the Society for Vascular Ultrasound (SVU). The consensus statement proposes a standardized nomenclature for arterial and venous spectral Doppler waveforms using a framework of key major descriptors and additional modifier terms. These key major descriptors and additional modifier terms are presented alongside representative Doppler waveforms, and nomenclature tables provide context by listing previous alternate terms to be replaced by the new major descriptors and modifiers. Finally, the document reviews Doppler waveform alterations with physiologic changes and disease states, provides optimization techniques for waveform acquisition and display, and provides practical guidance for incorporating the proposed nomenclature into the final interpretation report.

## Keywords

diagnostic imaging, Doppler waveform, duplex, spectral analysis, terminology, ultrasonography

<sup>1</sup>Department of Medicine, Division of Cardiovascular Medicine, Vanderbilt University Medical Center, Nashville, TN, USA

<sup>2</sup>Department of Medicine, Division of Cardiovascular Medicine, University of Virginia, Charlottesville, VA, USA

<sup>3</sup>Jobst Vascular Center, Toledo, OH, USA

<sup>4</sup>Vascular Surgery, Baylor Scott & White Health, Temple, TX, USA

<sup>5</sup>Department of Medicine, Division of Cardiovascular Medicine, Boston University, Boston, MA, USA

<sup>6</sup>Department of Medicine, Cardiovascular Division, Brigham and Women's Hospital and Harvard Medical School, Boston, MA, USA

<sup>7</sup>NAVIX Diagnostix, Inc., Taunton, MA, USA

<sup>8</sup>Diagnostic Ultrasound Technology, Bellevue College, Bellevue, WA, USA

<sup>9</sup>Albany Medical College, Albany, NY, USA

<sup>10</sup>North Country Vascular Diagnostics, Altamont, NY, USA

<sup>11</sup>Vascular Medicine Unit, CHU Rennes, Univ Rennes CIC1414, Rennes, France

<sup>12</sup>Vascular Diagnostic Education Services, Harrisburg, PA, USA

<sup>13</sup>Envoy Vascular, Athens, GA, USA

<sup>14</sup>Shugart Consulting, Greensboro, NC, USA

<sup>15</sup>Department of Cardiovascular Medicine, Mayo Clinic, Rochester, MN, USA

<sup>16</sup>Cardiovascular Surgery, Medical University of South Carolina, Florence, SC, USA

<sup>17</sup>Division of Vascular Surgery, University of Washington School of Medicine, Seattle, WA, USA

\*Representative of the Society for Vascular Medicine

\*\*Representative of the Society for Vascular Ultrasound

§Chair of writing committee

§§Co-Chairs of writing committee

## Corresponding author:

Esther SH Kim, Department of Medicine, Division of Cardiovascular Medicine, Vanderbilt University Medical Center, 1215 21<sup>st</sup> Ave South, Medical Center East, 5<sup>th</sup> Floor, South Tower, Nashville, TN 37232, USA.  
Email: esther.kim@vumc.org  
Twitter: @EstherSHKimMD

## Introduction

Noninvasive spectral Doppler waveform assessment is a principal diagnostic tool used in the diagnosis of arterial and venous disease states. With 200 million people affected by peripheral artery disease worldwide<sup>1,2</sup> and > 600,000 hospital admissions yearly for venous thromboembolic disease in the United States,<sup>3,4</sup> establishment and adoption of nomenclature for spectral Doppler waveform characterization is essential for communication of disease presence and severity. Overlapping and conflicting Doppler waveform terminologies are considerable,<sup>5,6</sup> and awareness of this issue was first published more than a decade ago.<sup>7</sup> Recognizing the need for standardization, the Society for Vascular Medicine (SVM) and the Society for Vascular Ultrasound (SVU) commissioned a writing committee to develop an expert consensus document on the nomenclature for spectral Doppler waveforms. The intent of this expert consensus document is to propose a common nomenclature for the description of arterial and venous Doppler waveforms in order to facilitate improved communication among all practitioners who care for vascular patients. The scope of the document is listed below, and a summary of the major consensus points is listed in Table 1. The writing committee was comprised of sonographer and physician members from SVM and SVU based on their extensive experience in the performance, interpretation, research, and/or teaching contributions to the field of vascular ultrasound. This document was peer reviewed within the SVM and SVU and endorsed by the SVM Board of Trustees and SVU Board of Directors.

### Scope of the consensus document

The purpose of this consensus statement is to:

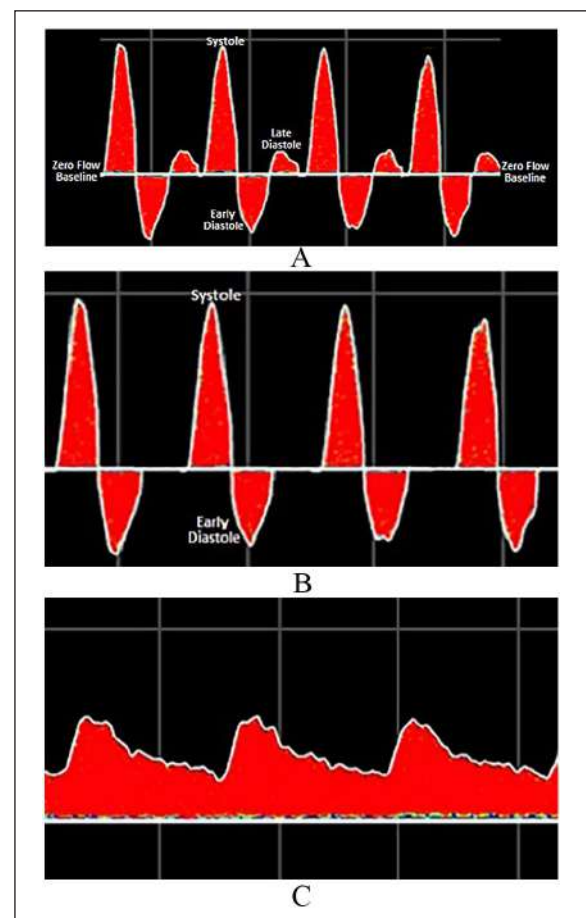
- Clarify and standardize key definitions and descriptors that are inherent to the analysis of arterial and venous Doppler waveforms.
- Review Doppler waveform alterations with physiologic changes and disease states.
- Provide Doppler transducer optimization techniques to enhance the quality and presentation of Doppler spectral waveform and color Doppler data.
- Provide guidance for applying waveform descriptors and modifiers – sonographer's report and physician's final interpretation.

### History

The initial descriptions of peripheral arterial Doppler waveforms were based on: (1) the audible presence or absence of the systolic and diastolic components of the cardiac cycle; and (2) the display of these flow components relevant to the zero-flow baseline on a recorded strip chart display. These characteristics were the origin of the Doppler waveform descriptors *triphasic*, *biphasic*, and *monophasic*<sup>8</sup> and the historical foundation for classifying blood flow in peripheral arteries.<sup>9,10</sup>

The *triphasic* waveform was recognized audibly and displayed as three distinct components of the cardiac cycle: (1) systole; (2) early diastolic flow reversal; and (3) a small forward flow reflective wave in late diastole (Figure 1A). The late diastolic component was absent in a *biphasic* waveform, leaving only systolic upstroke and early diastolic flow reversal as the audible and displayed cardiac components (Figure 1B). The original description of a *monophasic* waveform included the observation that the waveform did not cross the zero-flow baseline and was referred to as 'unidirectional'.<sup>10</sup> Following Doppler technological advancements, the monophasic term was used to describe waveforms that did not retain early diastolic flow reversal or lacked the reflective wave in late diastole. In early publications, monophasic waveforms exhibited only one audible or waveform display component that was likely caused by an arterial obstruction (Figure 1C).

The introduction of duplex ultrasound in the late 1970s was a major shift from indirect physiologic testing and the first significant change in Doppler waveform analysis. Duplex technology enabled the display of the full spectrum of frequencies within the Doppler sample volume. In the early days of duplex waveform analysis, spectral broadening was attributed to the spectral waveform features observed in areas of disturbed or turbulent flow.<sup>11</sup> These



**Figure 1.** Triphasic (A), biphasic (B), and monophasic (C) Doppler waveforms.

characteristics resulted in the addition of waveform descriptors such as ‘laminar’, ‘disturbed’, or ‘turbulent’ (Figure 2).

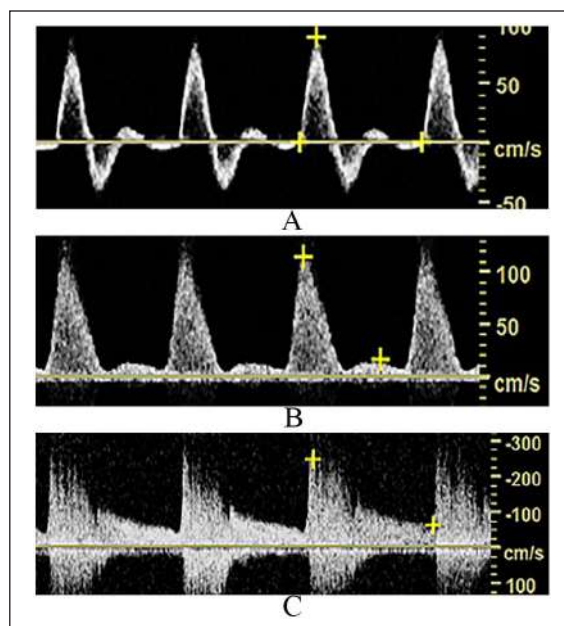
### Nature and impact of the problem

The waveform descriptors *triphasic*, *biphasic*, and *monophasic* have been used for more than 50 years, yet standardized application of these terms is not widely evident in the literature (Figure 3).<sup>12–14</sup> The term *triphasic*, depicting three phases including diastolic flow reversal, is the most consistently and commonly used descriptor<sup>5</sup> to characterize normal arterial blood flow; however, triphasic has also been used to describe high-resistive waveforms with two phases<sup>15</sup> and low-resistive waveforms with continuous forward flow throughout diastole.<sup>16</sup> These waveforms have also been described as *multiphasic*.<sup>17,18</sup> *Biphasic* has been used to characterize both normal<sup>19,20</sup> and abnormal arterial flow patterns.<sup>15,21</sup> Similar to its triphasic counterpart, the biphasic waveform has been depicted as high resistive with diastolic flow reversal<sup>22,23</sup> and low resistive with continuous forward flow throughout diastole.<sup>21,24</sup> Monophasic has most commonly been used to describe abnormal waveforms with a single phase found distal to a hemodynamically significant arterial obstruction,<sup>18,25</sup> but has also been employed to characterize abnormal blood flow proximal to a significant obstruction and from normal extremities following exercise and exposure to hyperemic conditions or medications<sup>21,24,26,27</sup> (Figure 4).

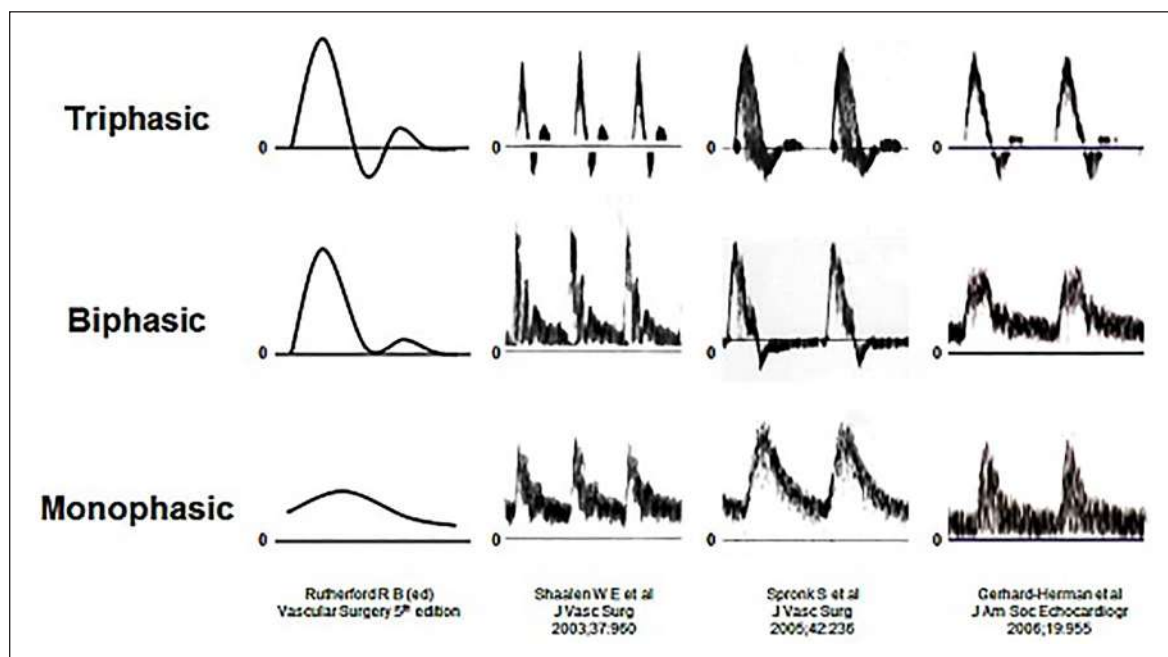
It should be emphasized that triphasic, biphasic, monophasic, and multiphasic are purely descriptor terminologies and are dependent on how the various terms are defined. In contrast, *normal* and *abnormal* are interpretative terms and depend on the specific vessel, vascular bed, pathology, and other factors. Each of the aforementioned waveform

descriptors may be normal or abnormal, depending on the clinical setting (e.g. a monophasic waveform is normal in a renal artery and abnormal in a brachial artery).

Additional confusion surrounding Doppler waveforms includes the term *phasicity* and utilization of a zero-flow baseline. Waveform phasicity has been described as a change in direction and/or velocity.<sup>28</sup> While the zero-flow reference point is crucial to delineating diastolic flow reversal, many publications depict arterial waveforms without a clearly delineated zero-flow reference point.<sup>5</sup>

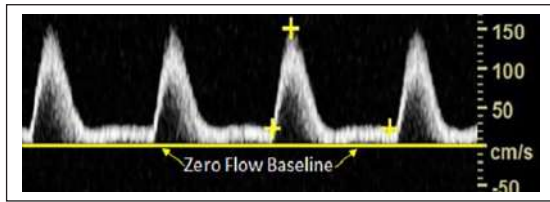


**Figure 2.** Spectral Doppler waveforms demonstrate laminar (A), disturbed (B), and turbulent (C) flow patterns.



**Figure 3.** Waveform illustrations from authoritative publications demonstrating the inconsistent characterization of triphasic, biphasic, and monophasic waveform descriptors.

Modified with permission from *Investigation of Vascular Disorders*, Nicolaidis AN, Yao JST (eds), p.543. © Elsevier, 1981.



**Figure 4.** Spectral Doppler illustrates monophasic waveforms.

The clinical impact of nonstandardized waveform nomenclature was studied in a survey of nearly 2000 ultrasound professionals. One-fifth of the respondents reported one or more occurrences of repeat arterial Doppler examinations because of lack of understanding of the terminology used to describe Doppler waveforms.<sup>29</sup> Standardization of Doppler waveform nomenclature is vital for the accurate and consistent communication of the results of vascular diagnostic tests and the prevention of inappropriate testing.

## Part I: Nomenclature

*Purpose: Clarify and standardize key definitions and descriptors that are inherent to the analysis of arterial and venous Doppler waveforms*

### Arterial nomenclature

The major descriptor, modifier terms, and their descriptions are listed in Tables 2 and 3.

**CONSENSUS POINT:** The reference baseline for spectral Doppler waveforms will refer to the *zero-flow baseline*.

**CONSENSUS POINT:** Arterial spectral Doppler and analog Doppler waveforms should be reported using key major descriptors: direction of flow, phasicity, and resistance. Modifier terms may be incorporated to provide additional information about waveform appearance.

The writing committee recommends that phasicity be described using the terms multiphasic and monophasic. Multiphasic waveforms cross the zero-flow baseline and contain both forward and reverse velocity components. Monophasic waveforms do not cross the zero-flow baseline and reflect blood which flows in a single direction for the duration of the cardiac cycle.

The writing committee recommends that arterial spectral Doppler waveforms be described as demonstrating high, intermediate, or low resistance. High-resistive waveforms have a sharp upstroke and brisk downstroke and may be either multiphasic or monophasic. Low-resistive waveforms contain a prolonged downstroke in late systole with continuous forward flow throughout diastole without an end-systolic notch. Low-resistive waveforms are monophasic. There is a hybrid waveform that is monophasic but has features of both high and low resistivity as it contains both brisk downstroke but also continuous forward flow

throughout diastole. This waveform has been variably labeled the ‘biphasic’ waveform in several prior publications<sup>5</sup> and has been the source of much confusion. Thus, the consensus is that waveforms with sharp upstroke, brisk downstroke, and continuous forward flow during diastole above the zero-flow baseline (monophasic) but with the presence of an end-systolic ‘notch’ (representing rapid deceleration during end systole followed by diastolic acceleration) will now be referred to as an intermediate resistive waveform.

As examples, Figures 1A and 1B would be described as multiphasic, high resistive, and Figure 1C would be described as monophasic, low resistive. Figure 2B would be described as monophasic, intermediate resistive. Figure 2C would be described as monophasic, low resistive with spectral broadening. As previously noted, the terms ‘normal’ and ‘abnormal’ are not used in these descriptors as ‘normal’ and ‘abnormal’ are interpretive terms that place the waveform into the text of location and physiologic conditions: a multiphasic, high-resistive waveform may be normal in a resting lower extremity artery but abnormal in an internal carotid artery. The nomenclature presented here serves only as descriptors of the waveforms, thus allowing interpretation of the waveforms to be performed within the appropriate clinical context.

### Venous nomenclature

The major descriptors, modifier terms, and their descriptions are listed in Tables 4 and 5.

**CONSENSUS POINT:** Venous spectral Doppler waveforms should be reported using key descriptors: direction of flow, flow pattern, and spontaneity in flow. Other modifier terms may be used to provide additional information about waveform appearance.

## Part 2: Doppler waveform alterations with physiologic changes and disease states

*Purpose: Review Doppler waveform alterations with physiologic changes and disease states*

### Peripheral arterial circulation

**Overview.** Multiple physiologic factors proximally, distally, and at the site being examined contribute to the morphology of the Doppler waveform. Metabolic demands of the tissue bed, changes in pressure, changes in resistance, wave propagation, and wave reflection all impact waveform patterns.

**Normal peripheral arterial waveforms.** The peripheral arterial circulation supplies the muscular tissues of the upper and lower extremities. Arterial Doppler waveforms may display both antegrade and retrograde waves and are subject to the effects of attenuation and amplification along the vascular tree. Reflection of the pulse wave can also occur at several sites including the aortic bifurcation and aortic branches.<sup>30</sup> The systolic component of an arterial waveform is produced by the contraction of the left ventricle

sending a bolus of blood out the ascending aorta, resulting in a rapid increase in volume and velocity.

The spectral display depicts a sharp upstroke or acceleration in an arterial waveform velocity profile from a normal vessel. In the absence of disease, the diastolic component in an arterial waveform reflects the vasoconstriction present in the resting muscular beds. Normal waveforms in a high-resistive bed will display a retrograde (reflected) wave in early diastole. A small antegrade component may be present in mid to late diastole as a result of an antegrade wave generated by proximal compliant large and medium arteries (Table 6).

Conditions that produce an increased flow to the limb muscles, such as exercise, increased limb temperature, and/or arteriovenous fistula, do so in part by dilating the arterioles in the muscle bed, allowing forward flow throughout diastole. Although the Doppler waveform generally demonstrates a narrow spectral bandwidth, some slight increase in spectral broadening may be noted dependent on the diameter of the arterial segment and the size of the Doppler sample volume (Table 6).

**Abnormal peripheral arterial waveforms.** The severity of reduction in lumen diameter is reflected in a continuum of changes in the waveform morphology (Table 7). Minimal diameter reduction results in slight disruption to laminar flow without significant increase in peak systolic velocity (PSV). Most notably, early diastolic reverse flow is maintained. Loss of the reverse flow component and transition from a multiphasic to monophasic flow pattern are apparent when the degree of narrowing is sufficient to cause a pressure-flow gradient at the site of stenosis. The severity of arterial compromise is reflected in the continual increase in peak systolic and end-diastolic velocities to a critical value consistent with a pre-occlusive lesion.

The waveform also indicates the location of arterial obstruction. Delayed systolic upstroke suggests flow-limiting disease proximal to the recording site. Distal to a stenosis, ischemia in the tissue bed will result in vasodilation and decreased resistance. Additionally, there is a decrease in distal pressure due to the pressure drop across the stenosis. This pressure drop, along with the lower resistance, results in increased diastolic flow throughout the cardiac cycle distal to a stenosis. Proximal to an occlusion or high-grade stenosis, the resistance will increase. The reflected wave or any antegrade diastolic flow, if normally present, may be reduced or absent and sequential flow-limiting lesions and collateral vessel capacity can affect waveform morphology at a given Doppler sampling location.

### Peripheral venous circulation

**Overview.** Numerous intrinsic and extrinsic factors influence the movement of venous blood. Intrinsic factors include the respiratory cycle, changes in central and segmental venous pressure gradients, vessel compliance, and valve function. Extrinsic factors include gravity, muscle pumps, atmospheric pressure, and external compression of veins, such as may occur from an overlying tumor, artery, mass or fluid collection.

**Normal peripheral venous waveforms.** Normal venous flow in the larger peripheral and more central veins examined in duplex protocols is spontaneous with low-velocity Doppler waveforms that reflect pressure gradient changes produced by respiratory and cardiac function. Flow velocities are very low in the smaller veins distally in the extremities and may not produce discernable Doppler signals in the resting state. Throughout the periphery, flow velocities vary with respiration due to the changes in intrathoracic and intra-abdominal pressures and are aptly called respirophasic. These patterns of respiratory variations in flow velocity can become suspended, severely dampened, or absent with shallow breathing or breath holding. Peripheral veins that are most distal to the heart, such as calf or forearm veins, demonstrate less spontaneity and respirophasicity compared to the veins closer to the heart. Cardiac filling and contraction also draws and pushes venous flow, with this influence normally stronger in veins closest to the heart termed pulsatile flow<sup>31,32</sup> (Table 8).

**Abnormal peripheral venous waveforms.** Evaluation for abnormal changes in waveform morphology includes appraisal of flow direction, responses to respiration and cardiac function, and response to physiologic maneuvers. Changes that are the result of central, systemic conditions will be seen bilaterally. Symmetry between left and right-side waveforms is an important aspect of duplex studies requiring comparison of spontaneous signals and response to physical maneuvers.

The normal antegrade flow direction in the venous system may become retrograde when there is valvular incompetence or occlusion in a more central venous segment. Continuous spontaneous venous flow also suggests a more central obstruction (Table 9). While the utilization of augmentation maneuvers remains controversial, advocates maintain it can be helpful in diagnosing a more central obstructive pathology and is discussed in the nomenclature section in greater detail. Although they may be seen with certain pathologies (Table 9), pulsatile waveforms are not normally observed in the lower extremity peripheral veins due to their distance from the heart. However, loss of this pulsatility is abnormal in central upper extremity and abdominal veins. Interpretation of venous waveform morphology is most often done without reporting angle-corrected velocity data, although measuring velocities is essential when evaluating a fistula or a venous stenosis.

### Cerebrovascular circulation

**Overview.** The bilateral extracranial cerebral vessels include the common carotid, external carotid, internal carotid, and vertebral arteries. Inflow to these vessels depends on the aortic valve, aortic arch, brachiocephalic, and subclavian arteries. Outflow from these vessels is determined by the status of the basal cerebral arteries (circle of Willis) and the rest of the intracranial cerebral circulation. With normal inflow, waveform features generally reflect the resistance of the distal vascular bed. Proximal occlusive lesions, focal

lesions in specific arterial segments, and changes in the resistance of the distal vascular bed all contribute to the changes observed in cerebrovascular flow waveforms.

**Normal cerebrovascular waveforms.** Normal flow waveforms in the cerebral arteries show a rapid systolic upstroke, reflecting normal proximal vessels and cardiac function, but the characteristics of the diastolic portion of the waveform are determined by the resistance of the distal vascular bed. Because brain tissue normally has a low vascular resistance, a normal internal carotid artery waveform shows a low-resistive pattern with relatively high diastolic velocities and forward flow throughout the cardiac cycle. In contrast, the normal external carotid artery supplies a high-resistive vascular bed (skin, muscle, bone) similar to that of peripheral arteries and displays a typical multiphasic arterial flow pattern. The common carotid artery supplies the internal and external carotid arteries, so the normal common carotid artery waveform contains features of both branch vessels. However, since the internal carotid has a much higher flow rate than the external carotid, the common carotid flow pattern tends to resemble the internal carotid, although typically with less diastolic flow. The normal vertebral artery flow waveform shows a low-resistive pattern like that of the internal carotid artery. As for arterial waveforms in general, the absence of spectral broadening in cerebrovascular waveforms indicates laminar flow. Table 10 illustrates the normal features of flow waveforms in the extracranial cerebral arteries.

**Abnormal cerebrovascular waveforms.** As in other segments of the arterial system, significant obstructive lesions involving inflow to the extracranial cerebral arteries result in waveforms with a delayed systolic upstroke, rounded systolic peak, and decreased peak velocities. Focal stenoses produce localized high-velocity jets and post-stenotic turbulence. Distal obstructive lesions cause increased vascular resistance, which appears in the waveform as decreased diastolic flow or reversed flow, features which are particularly noticeable in vessels that normally have a low-resistive flow pattern, such as the internal carotid and vertebral arteries. Table 11 illustrates the features of abnormal flow waveforms in the extracranial cerebral arteries.

**Abnormal carotid Doppler waveforms associated with cardiac disease.** There are several cardiac abnormalities which will alter the expected waveform patterns observed in the arteries. Many of the waveform alterations are commonly detected in the carotid arteries, while some can be appreciated as far distally as the femoral arteries. Observed waveform changes may vary depending on the severity of cardiac disease. Table 12 summarizes some of the more frequently encountered waveforms associated with various cardiac disorders.

### Mesenteric and renal arterial circulation

**Overview.** Multiple physiologic factors determine the shape of the renal and mesenteric Doppler waveforms, including the metabolic requirements of the end organ and

whether the images were obtained in the fasting or postprandial state.

**Normal mesenteric arterial waveforms.** The celiac artery has major branches (hepatic, splenic, and left gastric), which supply blood flow to the liver, spleen, pancreas, stomach, and superior portion of the small bowel. Because of the high oxygen demands of the organs supplied by the celiac artery and its branches, blood flow is not affected by digestion and peak systolic and end-diastolic velocities are not significantly altered postprandially.<sup>33</sup> In contrast, the superior mesenteric (SMA) and inferior mesenteric (IMA) arteries have multiple branches that carry blood flow to the pancreatic head and the muscular tissues of the small and large intestine. Changes in Doppler waveform morphology in these vessels with fasting and in the postprandial state are shown in Table 13.

**Abnormal mesenteric arterial waveforms.** Significant stenosis in the mesenteric vessels is accompanied by changes in the Doppler waveform seen in other vascular beds: elevated peak systolic and diastolic velocities, spectral broadening, and, when severe, a prolonged upstroke may be present (Table 14). Mesenteric artery occlusion should be suspected when flow cannot be detected in an imaged artery after ultrasound system controls for spectral and/or color Doppler have been optimized for slow flow.

There are few well-validated diagnostic criteria for the inferior mesenteric artery;<sup>34,35</sup> however, the Doppler waveform will mimic those of the fasting, postprandial, and stenotic superior mesenteric artery with, most often, lower peak systolic velocities in the fasting and postprandial states.

**Normal renal arterial waveforms.** The kidneys are high flow demand end-organs, which receive blood from one or more renal arteries. The Doppler waveform will demonstrate a rapid upstroke, sharp peak, and a low-resistive, monophasic waveform consistent with continuous diastolic forward flow (Table 15).

**Abnormal renal arterial waveforms.** Blood flow via adrenal or capsular collaterals may be found in the hilar and parenchymal arteries in patients with renal artery occlusion. The waveform pattern in these vessels will be antegrade, low resistive, dampened, and monophasic (Table 15).

Resistance to arterial inflow to the renal parenchyma may result from a variety of pathologic processes including, but not limited to, interstitial fluid accumulation, hydronephrosis, space-occupying lesions, acute tubular necrosis, and glomerulonephritis.

### Mesenteric, renal, hepatic, and portal venous circulation

These veins often will present with unique flow patterns, which are described in detail in Table 16.

**Abnormal hepatic and portal veins.** Cardiac and liver abnormalities, including transjugular intrahepatic portosystemic shunts, lead to changes in hepatic and portal vein waveform patterns, as noted in Table 17.

### Part 3: Waveform optimization

*Purpose: Provide Doppler transducer optimization techniques to enhance the quality and presentation of Doppler spectral waveform and color Doppler data*

**CONSENSUS POINT: Optimization techniques should be used to provide quality Doppler waveforms for accurate interpretation.**

Waveform optimization is an integral part of Doppler ultrasound and plays a vital role in appropriate creation and interpretation of spectral waveforms and color data. The essential elements for image optimization and potential artifacts that can occur while performing Doppler ultrasound, along with solutions to improve image quality, are presented in Table 18.

### Part 4: Interpretation and reporting

*Purpose: Provide interpretation and reporting examples to facilitate use of the recommendations outlined in this consensus document*

**CONSENSUS POINT: Waveform descriptors and modifiers, velocity measurements, and image descriptors are test findings, not interpretations. To be clinically useful to the ordering provider, test data, including waveform findings, should be used by the interpreting physician along with exam-specific, validated diagnostic criteria to determine the final interpretation or conclusion of the vascular study.**

- The sonographer will complete a written description of the ultrasound examination, including the

study indication, pertinent history, and appropriate images, along with velocity measurements and waveform descriptions. A standardized description of waveforms allows the waveform display to be recreated in words, providing useful information relevant to the clinical indication for the examination.

- The conclusion/interpretation is most helpful to the referring physician if it includes not only the diagnostic findings but also the clinical indication and prior relevant examinations.

Illustrative case examples are provided in the supplemental material, which is available online with the article.

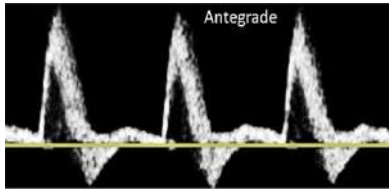
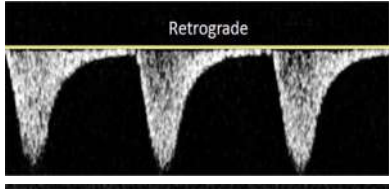
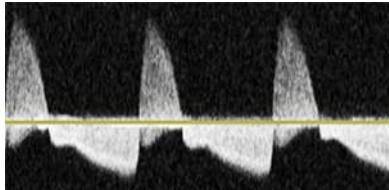
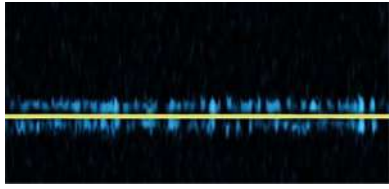
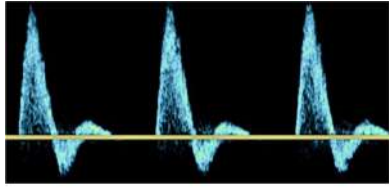
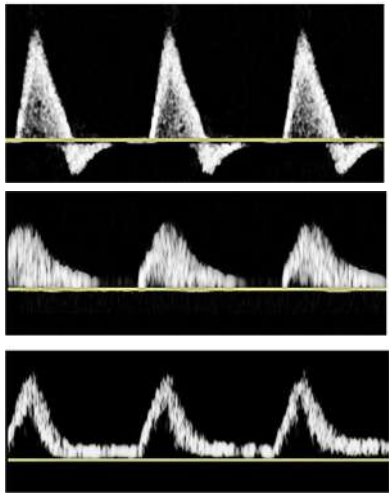
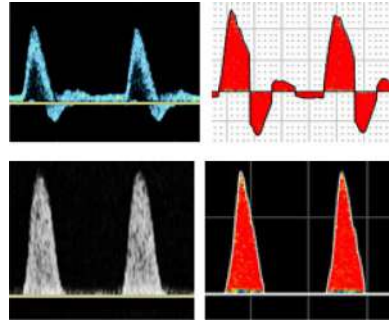
### Summary

Spectral Doppler waveform assessment has been the principal diagnostic tool for the noninvasive diagnosis of peripheral artery and venous disease since the 1980s.<sup>36,37</sup> The absence of uniformly accepted, standardized descriptors for arterial and venous Doppler waveforms has been a long-standing point of controversy<sup>38</sup> and the main impetus for the development of this consensus statement, which is a major step towards clarifying and standardizing the key definitions and descriptors that are inherent to the analysis of arterial and venous Doppler waveforms. All interpreting physicians and sonographers should be able to describe Doppler waveforms, be able to identify the changes which occur with physiologic and disease states, and effectively communicate these waveform characteristics to interpreting physicians so that consistent information is given to referring providers. This consensus statement outlines a simple nomenclature for the description of arterial and venous Doppler waveforms (Table 1), which will hopefully alleviate the confusion regarding Doppler waveform interpretation that has plagued the field for decades.

**Table 1.** Summary of consensus points.

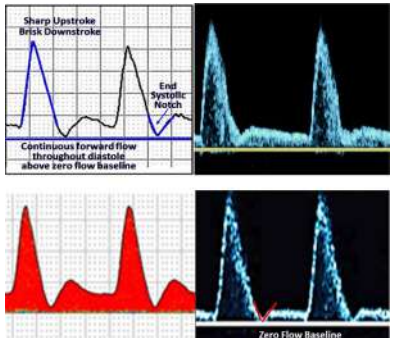
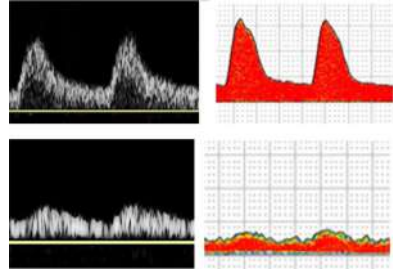
<ul style="list-style-type: none"> <li>• The reference baseline for spectral Doppler waveforms will refer to the <i>zero-flow baseline</i>.</li> <li>• All arterial and venous waveforms will be described using key descriptors and modifiers as listed below.</li> <li>• Optimization techniques should be used to provide quality Doppler waveforms for accurate interpretation.</li> <li>• Waveform descriptors and modifiers, velocity measurements, and image descriptors are test findings, not interpretations. To be clinically useful to the ordering provider, test data, including waveform findings, should be used by the interpreting physician along with exam-specific, validated diagnostic criteria to determine the final interpretation or conclusion of the vascular study.</li> </ul>		
Arterial	Key major descriptors	<ul style="list-style-type: none"> <li>• Flow direction (antegrade, retrograde, bidirectional, absent)</li> <li>• Phasicity (multiphasic, monophasic)</li> <li>• Resistance (high, intermediate, low)</li> </ul>
	Additional modifier terms may also be utilized	<ul style="list-style-type: none"> <li>• Upstroke (rapid, prolonged)</li> <li>• Sharp peak</li> <li>• Spectral broadening</li> <li>• Staccato</li> <li>• Dampened</li> <li>• Flow reversal</li> </ul>
Venous	Key major descriptors	<ul style="list-style-type: none"> <li>• Flow direction (antegrade, retrograde, absent)</li> <li>• Flow pattern (respirophasic, decreased, pulsatile, continuous, regurgitant)</li> <li>• Spontaneity (spontaneous, nonspontaneous)</li> </ul>
	Additional modifier terms may also be utilized	<ul style="list-style-type: none"> <li>• Augmentation (normal, reduced, absent)</li> <li>• Reflux</li> <li>• Fistula flow</li> </ul>

**Table 2.** Arterial waveform nomenclature major descriptors.

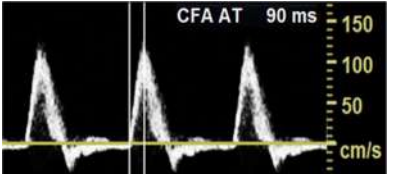
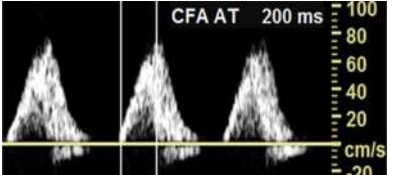
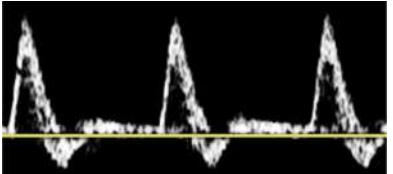
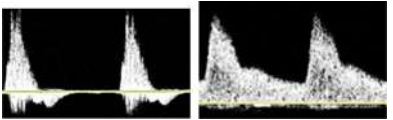
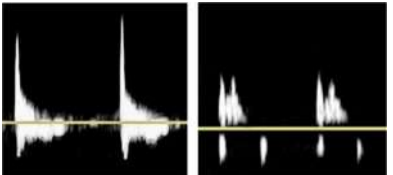
Major descriptor	Major descriptor terms and definitions	Waveform figure
<b>FLOW DIRECTION</b>	<p><b>Antegrade</b>  <i>Previous alternate term: forward flow</i>                      Blood flows in the normal direction for the artery being evaluated.</p>	
	<p><b>Retrograde</b>  <i>Previous alternate term: reverse flow</i>                      Blood flows opposite to the normal direction for the artery being evaluated.</p>	
	<p><b>Bidirectional</b>  <i>Previous alternate term: to-fro</i>                      Blood flow enters and leaves a contained space via the same orifice.</p>	
	<p><b>Absent</b>                      No blood flow is detected with an absent spectral Doppler signal.</p>	
<b>PHASICITY</b>	<p><b>Multiphasic</b>  <i>Previous alternate terms: triphasic; biphasic</i>                      Waveform crosses the zero-flow baseline and contains both forward and reverse velocity components.</p>	
	<p><b>Monophasic</b>                      Waveform does not cross the zero-flow baseline throughout any part of the cardiac cycle; blood flows in a single direction.  <i>Note: if the waveform does not cross the zero-flow baseline it is considered monophasic.</i></p>	
<b>RESISTANCE</b>	<p><b>High resistive</b>  <i>Key features: sharp upstroke and brisk downstroke, with or without diastolic flow reversal.</i></p>	

(Continued)

**Table 2.** (Continued)

Major descriptor	Major descriptor terms and definitions	Waveform figure
<b>RESISTANCE</b>	<p><b>Intermediate resistive</b>  <i>Key features:</i> sharp upstroke, brisk downstroke, visible presence of an end-systolic notch and continuous forward flow throughout diastole that is above the zero-flow baseline. In contrast to low resistance, the intermediate resistive waveform contains a rapid deceleration at end systole followed by a diastolic acceleration with continuous forward flow.                      The waveform pattern suggests vasodilation and can be the result of exertion (exercise), increased temperature, vasodilator drugs, or a severe arterial obstruction distal to the point of Doppler insonation.<sup>39</sup></p>	
	<p><b>Low resistive</b>  <i>Key features:</i> a prolonged downstroke in late systole and continuous forward flow throughout diastole.  <i>Note:</i> key feature: prolonged diastolic downslope with the presence of pandiastolic flow. In contrast to intermediate resistance, the low-resistive waveform contains a continuous and prolonged diastolic forward flow without the presence of an end-systolic notch.</p>	

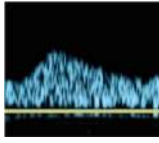
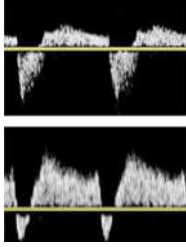
**Table 3.** Arterial waveform modifier terms.

Waveform characteristics and definitions	Waveform figure
<p><b>Rapid upstroke</b>                      Nearly vertical slope or steep rise to peak systole. AT &lt; 140 ms has been used for the CFA (measured from start of systole to mid-systole).<sup>40</sup></p>	
<p><b>Prolonged upstroke</b>  <i>Previous alternate terms:</i> tardus; delayed; damped                      Abnormally gradual slope to peak systole. AT &gt; 140 ms has been used for the lower extremity CFA.<sup>40</sup></p>	
<p><b>Sharp peak</b>                      Sharp, single, and well-defined peak, often with maximum velocity, within range of the artery being interrogated.</p>	
<p><b>Spectral broadening</b>  <i>Previous alternate terms:</i> nonlaminar; turbulent; disordered; chaotic                      Widening of the velocity band in the spectral waveform; a 'filling in' of the clear 'window' under the systolic peak.  <i>Note:</i> spectral broadening is commonly seen in turbulent flow but can also be seen in the absence of turbulence.</p>	
<p><b>Staccato</b>                      A very high-resistance pattern with a short 'spike' of velocity acceleration and deceleration followed by a short and low-amplitude diastolic signal reflecting low antegrade flow.</p>	

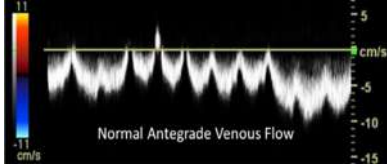

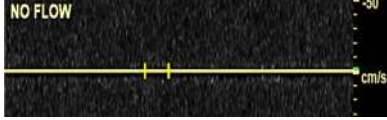
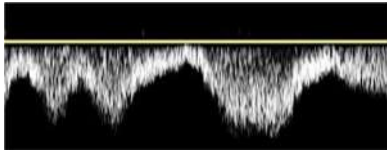
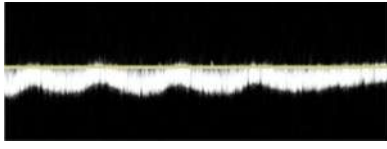
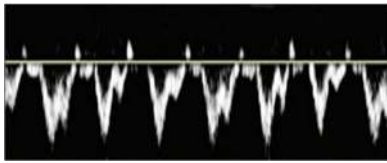
AT, acceleration time; CFA, common femoral artery.

(Continued)

**Table 3.** (Continued)

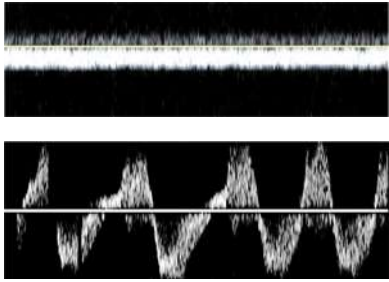
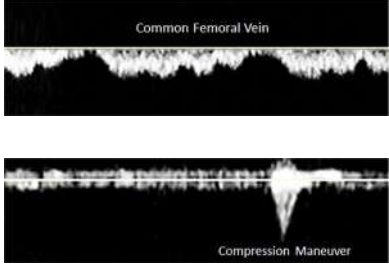
Waveform characteristics and definitions	Waveform figure
<p><b>Dampened</b>  <i>Previous alternate terms: parvus et tardus; attenuated; blunted</i>                      Combined finding of an abnormal upstroke (delayed) and peak (broad), often with decreased velocity.</p>	
<p><b>Flow reversal</b>  <i>Previous alternate terms: pre-steal; competitive flow; oscillating</i>                      Flow that changes direction, not as part of normal diastolic flow reversal, which may be transient (positional) or consistent with each cardiac cycle (systole/diastole).</p>	

**Table 4.** Venous waveform nomenclature major descriptors.

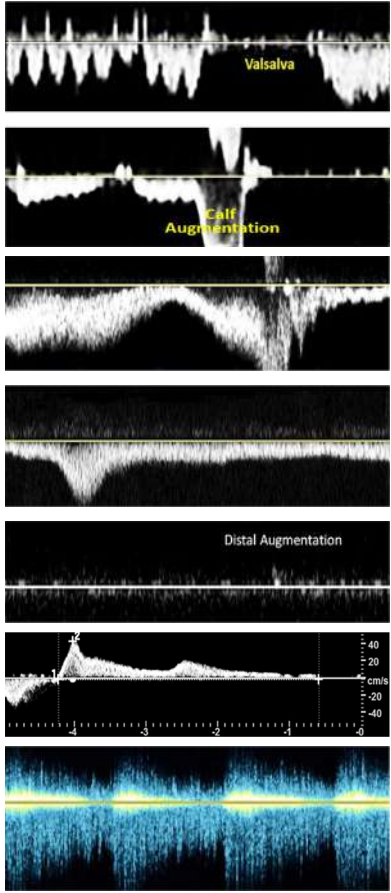
Major descriptor	Major descriptor terms and definitions	Waveform figure
<b>FLOW DIRECTION</b>	<p><b>Antegrade</b>  <i>Previous alternate terms: central or forward</i>                      Blood flow in the normal direction for the vein being evaluated.</p>	
	<p><b>Retrograde</b>  <i>Previous alternate terms: peripheral or reverse</i>                      Blood flow opposite to the normal direction for the vein being evaluated.</p>	
	<p><b>Absent</b>                      No blood flow is detected with an absent spectral Doppler signal.</p>	
<b>FLOW PATTERN</b>	<p><b>Respirophasic</b>  <i>Previous alternate term: respiratory phasicity</i>                      Cyclical increase and decrease in flow velocity, which correlates with respiratory phases.</p>	
	<p><b>Decreased</b>  <i>Previous alternate terms: dampened; blunted</i>                      Respirophasic flow is decreased if it demonstrates less variation with the respiratory cycle than normal for the segment, or in comparison to the contralateral segment.</p>	
<b>FLOW PATTERN</b>	<p><b>Pulsatile</b>  <i>Previous alternate term: cardiophasic</i>                      Cyclical increase and decrease, which inversely correlates with the cardiac cycle.</p>	

(Continued)

**Table 4.** (Continued)

Major descriptor	Major descriptor terms and definitions	Waveform figure
	<p><b>Continuous</b> Characterized by the lack of respiratory or cardiac influence on flow velocity variation resulting in a steady and consistent Doppler signal with minimal to no variation in flow.</p> <p><b>Regurgitant</b> Similar to pulsatile flow, there is cyclical increased and decreased flow that varies with the cardiac cycle; however, flow has similar amplitude in forward and reverse directions – typically seen with severe tricuspid regurgitation.</p>	
<b>SPONTANEITY</b>	<p><b>Spontaneous</b> Blood flow is spontaneous when it is observed actively moving in a vein without any external maneuvers such as Valsalva or muscle contraction or compression distal to the vein being evaluated.</p> <p><b>Nonspontaneous</b> Blood flow is not actively observed in a vein and only noted with maneuvers such as Valsalva or muscle contraction or compression distal to the vein being evaluated.</p>	

**Table 5.** Venous waveform modifier terms.

Waveform characteristics and definitions	Waveform figure
<p><b>Augmentation</b> Changes in venous flow velocity in response to physical maneuvers: increased proximal pressure lowers or stops flow with velocity increase on release (top); distal muscle compression increases flow with velocity low or absent on release (bottom).</p> <p><b>Normal augmented</b> Discrete instantaneous increase in venous antegrade flow velocity in response to distal muscle contraction or compression maneuver.</p> <p><b>Reduced augmented</b> <i>Previous alternate terms: decreased; blunted; dampened</i> Loss of increased venous flow velocity (dampened augmentation) in response to adequate distal muscle contraction or compression maneuver compared to contralateral limb.</p> <p><b>Absent augmented</b> No increase in venous flow/return in response to distal muscle contraction or compression maneuver.</p> <p><b>Reflux</b> Persistent retrograde flow beyond the normal venous valve closure time, typically noted upon release of distal compression. Also noted in response to Valsalva maneuver.</p> <p><b>Fistula flow</b> <i>Previous alternate terms: arterialized; fistulous</i> Venous flow with an arteriovenous fistula becomes pulsatile due to direct communication with an artery; sharp peaks often appearing pulsatile with spectral broadening.</p>	

**Table 6.** Physiologic state of normal peripheral arterial waveforms.

In the resting state, the normal waveform of all peripheral arteries is multiphasic with rapid systolic acceleration, sharp systolic peak, reverse diastolic flow, and low, or absent, end-diastolic forward flow

**Physiologic state and explanation**

Waveform figure

**Normal resting inflow arteries**

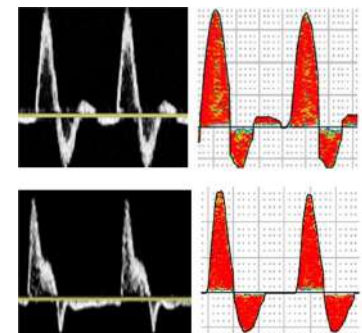
*Lower: common, external, and internal iliac artery*

*Upper: innominate and subclavian artery*

The PW Doppler spectral bandwidth is narrow throughout the cardiac cycle, consistent with laminar flow.

Minimally increased spectral broadening may be noted in the internal iliac artery secondary to the size of the Doppler sample volume and the smaller vessel diameter compared to the common and external iliac arteries.

The terms spectral bandwidth and spectral broadening are not applicable to analog CW Doppler waveforms.

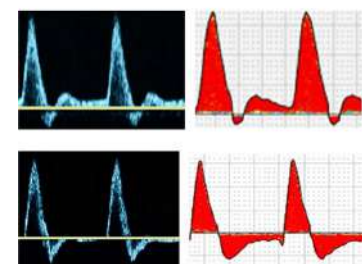


**Normal resting outflow arteries**

*Lower: common femoral, profunda femoris (deep femoral), superficial femoral, and popliteal artery*

*Upper: axillary and brachial artery*

In normal thigh arteries, there may be a slight decrease in PSV compared to PSV in the normal inflow arteries.

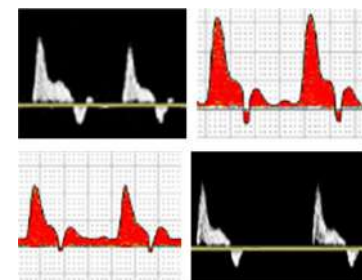


**Normal resting run-off arteries**

*Lower: anterior tibial, posterior tibial, peroneal artery*

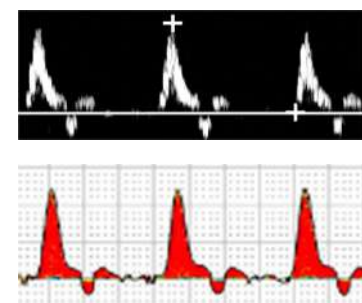
*Upper: radial, ulnar artery*

The PW Doppler spectral bandwidth remains consistent with laminar flow, although a slight increase in spectral broadening may be noted secondary to the size of the Doppler sample volume and the small vessel diameters. No significant difference is noted in PSV among the three calf arteries or two forearm arteries.



**Normal resting plantar, palmar, and digital arteries**

The flow pattern remains laminar, although a slight increase in the PW spectral bandwidth may be noted secondary to the size of the Doppler sample volume and the small diameter of the plantar and digital arteries.



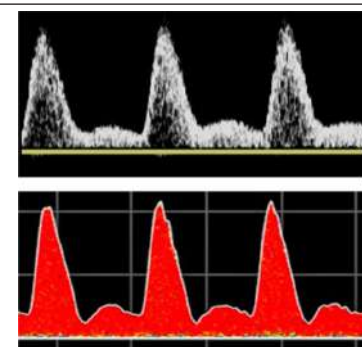
**Changes in vascular resistance associated with exercise and increased body temperature**

Waveform figure

**Normal peripheral arterial waveforms following exercise or resulting from increased body temperature**

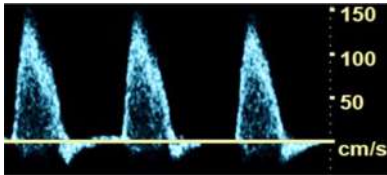
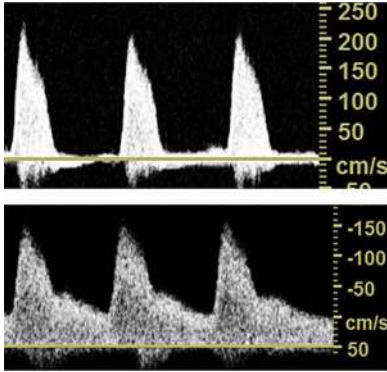
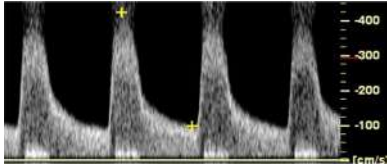
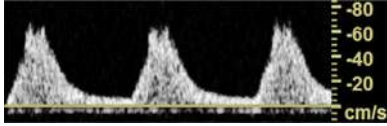
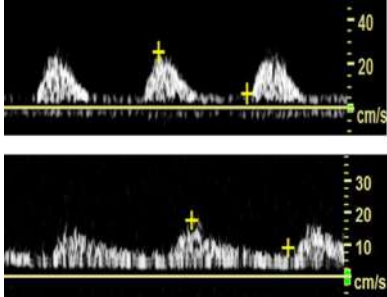
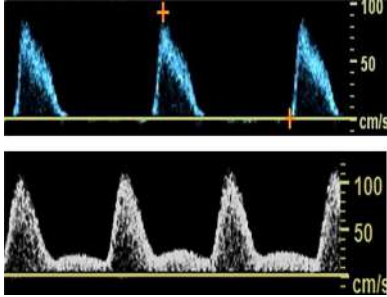
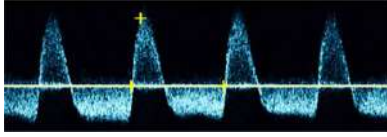
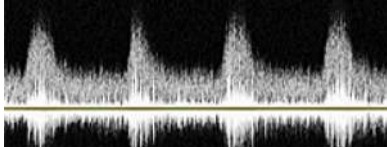
The increased flow demand and decreased vascular resistance associated with exercising muscle, increased body temperature, or focal inflammation results in continuous forward flow.

PSV can increase significantly (e.g. external iliac artery) as a result of exercise, even when the artery is normal.


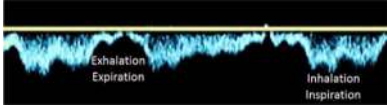
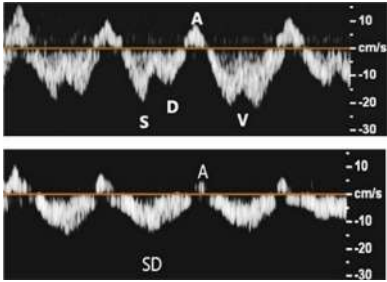
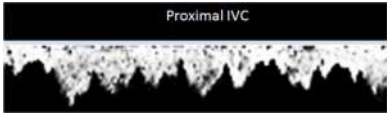


CW, continuous-wave; PSV, peak systolic velocity; PW, pulsed-wave.

**Table 7.** Pathophysiologic state of abnormal peripheral arterial waveforms.

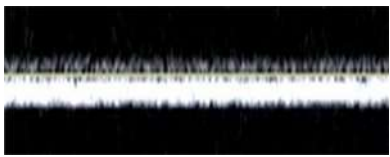

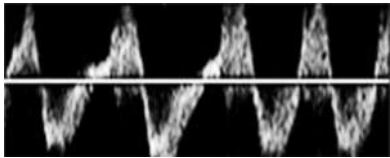
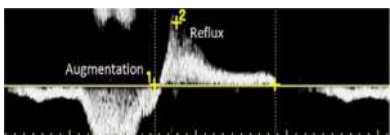
Pathophysiologic state and explanation	Waveform figure
<p><b>Peripheral artery: &lt; 50% diameter stenosis</b>            PSV increases slightly but is less than double that in the normal adjacent proximal segment (velocity ratio &lt; 2).<sup>41</sup> Typically, there is a multiphasic waveform with rapid upstroke and no appreciable increase in diastolic velocity. Spectral broadening is pansystolic.</p>	
<p><b>Peripheral artery: 50–74% diameter stenosis</b>            When the lumen of the artery is significantly narrowed, a pressure-flow gradient is present at the stenotic site. PSV increases by more than 100% (velocity ratio &gt; 2) compared to the normal adjacent proximal segment.<sup>41</sup>            The early diastolic reverse flow component is commonly lost (may be residual in a high-velocity state with extensive collateralization) with continuous, pandiastolic forward flow in response to decreased vascular resistance in the distal tissue bed. Spectral broadening is present.</p>	
<p><b>Peripheral artery: &gt; 75% diameter stenosis</b>            Severe arterial narrowing results in at least a fourfold increase in PSV (velocity ratio &gt; 4) compared to the normal proximal adjacent segment.<sup>41</sup> The waveform is monophasic, diastolic velocity may be increased, and a spectral bruit is commonly noted adjacent to the zero-flow baseline.</p>	
<p><b>Peripheral artery – distal to flow-reducing stenosis</b>            Waveform is monophasic with prolonged upstroke and PSV is decreased. Spectral broadening is present.</p>	
<p><b>Peripheral artery – distal to occlusion</b>            Waveform is dampened and monophasic.</p>	
<p><b>Peripheral artery – proximal to occlusion</b>            In the absence of flow-limiting stenosis proximal to the site of Doppler sampling, the waveform is characterized by rapid upstroke and may be high resistive or intermediate resistive.</p>	
<p><b>Pseudoaneurysm</b>            Flow is bidirectional (to-fro) through the neck or tract of the arterial pseudoaneurysm. The waveform has a rapid systolic upstroke with exaggerated deceleration, and an elongated and prominent reverse flow component.</p>	
<p><b>Arteriovenous fistula</b>            Blood flow from a high-pressure artery into a low-pressure vein results in spectral broadening and elevated systolic and diastolic velocities. Continuous forward flow is noted throughout the cardiac cycle.</p>	

**Table 8.** Physiologic state of normal peripheral venous waveforms.

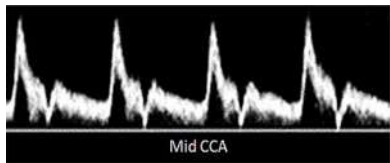
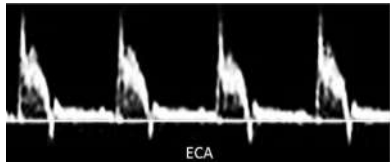
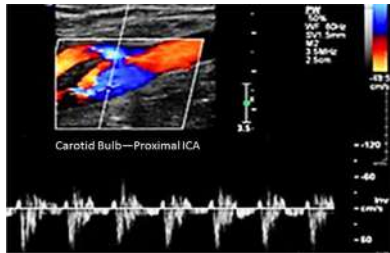
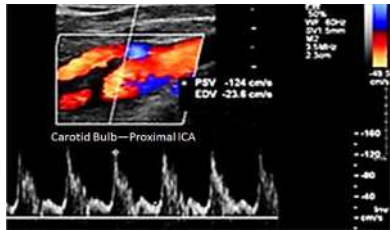
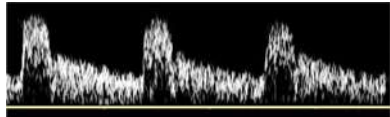
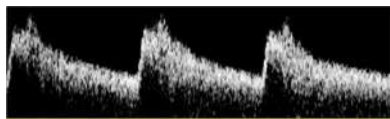
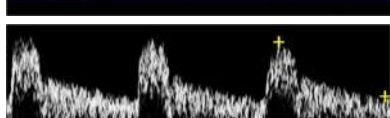
Physiologic state and explanation	Waveform figure
<p><b>Peripheral veins (iliac to calf veins and brachial to forearm veins)</b></p> <p><b>Lower extremity – normal respirophasic</b> Antegrade flow decreases with inspiration due to higher intra-abdominal pressure and increases with expiration due to decreased intra-abdominal pressure.</p>	
<p><b>Upper extremity – normal respirophasic</b> Antegrade flow increases with inspiration due to negative intrathoracic pressure and decreases with expiration due to increased intrathoracic pressure.</p>	
<p><b>Central veins (internal jugular, subclavian, axillary, IVC)</b></p> <p><b>Normal pulsatile</b> Subclavian vein waveforms demonstrate pulsatility due to the proximity to the heart and transmission of right atrial pressure. Pulsatile venous flow demonstrating antegrade flow with S and A-waves during early systole and diastole, V-notching during late systole, and A-wave during right atrial contraction. Pulsatile venous flow demonstrating antegrade flow with so-called S-D complex in systole and early diastole, and possible retrograde flow with A-wave during right atrial contraction.</p>	
<p><b>Proximal IVC – normal pulsatile</b> IVC pulsatility due to the effects of right atrial pressure and function because of proximity to the heart.</p>	

IVC, inferior vena cava.

**Table 9.** Pathophysiologic state of abnormal peripheral venous waveforms.

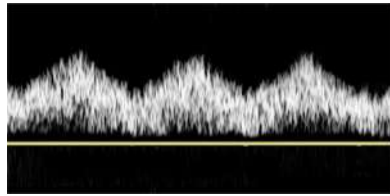
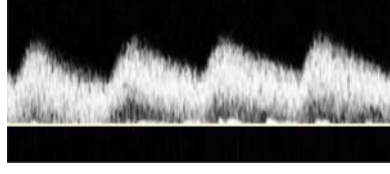
Pathophysiologic state and explanation	Waveform figure
<p><b>Continuous</b> A steady and unwavering waveform identifies a more central obstruction (proximal to site of insonation) intrinsic to the veins (fully or partially occluding thrombus or stenosis) or from extrinsic compression. The increased venous pressure at the Doppler sample level obviates the influence of respiratory and cardiac factors on the waveform.</p>	
<p><b>Pulsatile</b> An abnormal finding in lower extremity veins seen with elevated central venous pressure from heart failure, tricuspid valve regurgitation, pulmonary hypertension, and elevated right heart pressures or dysfunction.</p>	
<p><b>Regurgitant</b> Increased right atrial pressure creating a form of flow pattern similar in antegrade and retrograde components. Unlike pulsatile flow – where the intensity of the retrograde component is far less than the antegrade component.</p>	
<p><b>Reflux</b> Retrograde flow due to abnormal valve cusps and/or vein distention leading to incomplete valve coaptation. The definition of reflux varies by location, but can be timed on the spectral display as flow in the opposite direction of the zero-flow baseline from normal antegrade flow.</p>	

**Table 10.** Normal cerebrovascular waveforms.

Physiologic state and explanation	Waveform figure
<p><b>Normal CCA</b> Minimal or no reverse flow and relatively high diastolic flow from the more pronounced effect of the low-resistance internal carotid (vs the high-resistance external carotid).</p>	 <p style="text-align: center;">Mid CCA</p>
<p><b>Normal ECA</b> Presence of a reverse flow phase in late systole or early diastole and a multiphasic flow pattern are characteristics of an artery supplying a high-resistance vascular bed.</p>	 <p style="text-align: center;">ECA</p>
<p><b>Normal proximal ICA</b> <i>With flow separation along the outer wall</i> The carotid bulb has a diverging–converging geometry resulting in helical or oscillating flow patterns along the outer wall that are separate from the more rapid forward flow along the inner wall or flow divider – an area referred to as ‘flow separation’ or ‘boundary layer separation’. In the example, the sample volume is placed along the bulb outer wall and the low-velocity alternating forward and reverse flow pattern is typical of an area of flow separation.</p>	 <p style="text-align: center;">Carotid Bulb—Proximal ICA</p>
<p><b>Normal proximal ICA</b> <i>With forward flow along flow divider</i> In this example, the Doppler sample volume is placed along the flow divider in the carotid bulb, and the flow pattern shows mostly forward flow throughout the cardiac cycle, characteristic of the ICA. Some cardiac cycles show minimal reverse flow, most likely an effect of the adjacent area of flow separation in the bulb (see <i>outer wall</i> example above).</p>	 <p style="text-align: center;">Carotid Bulb—Proximal ICA</p> <p style="text-align: right;">PSV -124 cm/s EDV -23.8 cm/s</p>
<p><b>Normal mid-ICA</b> Forward flow throughout the cardiac cycle and relatively high diastolic flow velocities are characteristic of an artery perfusing a low-resistance vascular bed.</p>	
<p><b>Normal distal ICA</b> Forward flow throughout the cardiac cycle and relatively high diastolic flow velocities are noted. There may be an increase in PSV relative to the proximal and mid-segments of the ICA associated with vessel tapering.</p>	
<p><b>Normal vertebral artery</b> Forward flow throughout the cardiac cycle and relatively high diastolic flow velocities are noted. The flow pattern is similar to that of the ICA.</p>	

CCA, common carotid artery; ECA, external carotid artery; ICA, internal carotid artery; PSV, peak systolic velocity.

**Table 11.** Abnormal cerebrovascular waveforms.

Pathophysiologic state and explanation	Waveform figure
<p><b>CCA: distal to innominate artery stenosis (right side)</b> Prolonged upstroke, decreased peak systolic velocities, and a dampened peak are all typical features produced by a proximal obstructive lesion. There is forward flow throughout the cardiac cycle. Some spectral broadening is present, but the relatively clear (black) ‘window’ under the systolic portion of the waveform suggests minimal turbulence, consistent with the relatively large distance between the innominate artery stenosis and the mid-CCA.</p>	
<p><b>CCA: distal to proximal CCA stenosis</b> The CCA waveform demonstrates prolonged upstroke, decreased PSV, and a dampened peak. There is forward flow throughout the cardiac cycle and spectral broadening indicates turbulence from the more proximal CCA lesion.</p>	

CCA, common carotid artery; PSV, peak systolic velocity.

(Continued)

**Table 11.** (Continued)

Pathophysiologic state and explanation

Waveform figure

**CCA: with ipsilateral ICA occlusion**

The CCA waveform demonstrates an atypical high-resistive pattern with a small reverse flow phase in late systole and absent diastolic flow. In the setting of an ipsilateral ICA occlusion, the CCA waveform resembles that of the ECA. Rapid upstroke indicates normal inflow.

**ICA: distal to CCA stenosis**

The ICA waveform shows a prolonged upstroke and spectral broadening. There is forward flow throughout the cardiac cycle and relatively high diastolic flow, characteristic of an artery perfusing a low-resistive vascular bed.

**ICA: < 50% stenosis**

Peak velocities in this proximal ICA are below the commonly used threshold of 125 cm/sec for a  $\geq 50\%$  ICA stenosis.<sup>42</sup> Spectral broadening throughout the cardiac cycle represents turbulent flow produced by the stenotic lesion.

**ICA: 50–69% stenosis**

Peak velocities in this ICA are between 125 and 230 cm/sec and EDV are  $< 100$  cm/sec. These velocities are consistent with a 50–69% ICA stenosis.<sup>42</sup> The absence of spectral broadening is most likely due to the location of the Doppler sample volume within or just distal to the high-velocity jet produced by the stenosis.

**ICA: > 70% stenosis**

This focal high-velocity jet is produced by severe stenosis in the proximal ICA and has a PSV of  $\sim 500$  cm/sec and an EDV of almost 200 cm/sec. These are features of a  $> 70\%$  stenosis.<sup>42</sup> Extensive spectral broadening is also present.

**ICA near occlusion ('string sign')**

The waveform shows an uncommon flow pattern that occurs in a lumenally compromised ICA stenosis that often extends intracranially. In this setting, a focal high-velocity jet may not be present, and the waveform often demonstrates decreased velocities.

**ICA: with distal ICA stenosis**

Rapid systolic acceleration or upstroke indicates normal inflow, but rapid deceleration with low velocity or absent flow throughout diastole indicates abnormally increased distal vascular resistance.

**ECA stenosis**

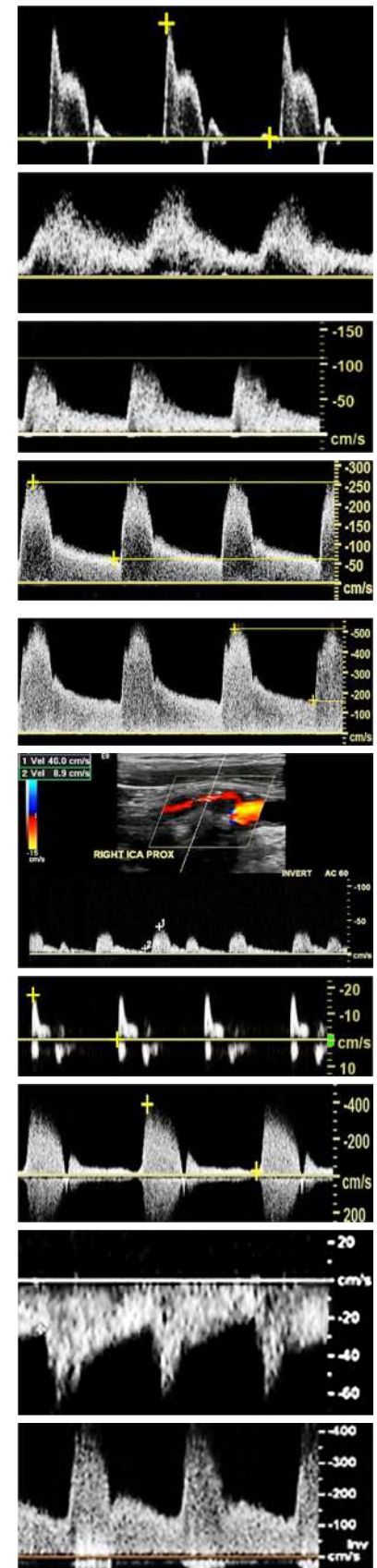
Increased peak velocities and extensive spectral broadening indicate a stenosis in the proximal ECA. Other features, such as a reverse flow phase in late systole and a multiphasic flow pattern, are characteristic of the ECA.

**ECA: with reversed flow due to CCA occlusion**

Delayed systolic acceleration indicates abnormal inflow through a collateral bed. Retrograde flow direction is present throughout the cardiac cycle. The relatively high diastolic flow is characteristic of flow to a low-resistive vascular bed. This pattern can be described as 'internalized' because the waveform resembles that of a typical ICA.

**Vertebral artery stenosis**

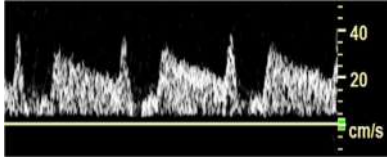
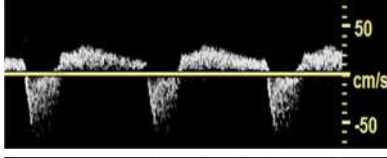
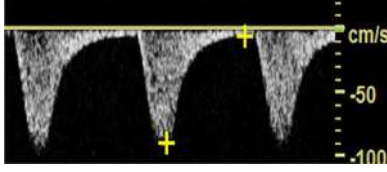
A focal high-velocity jet is produced by a severe stenosis in the proximal vertebral artery. There is a marked increase in both the peak velocities and EDV with extensive spectral broadening.



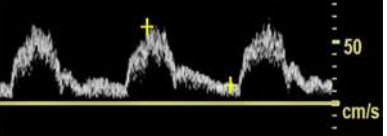
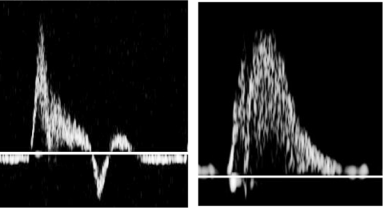
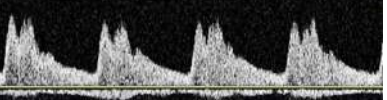
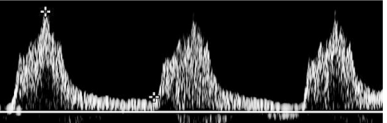
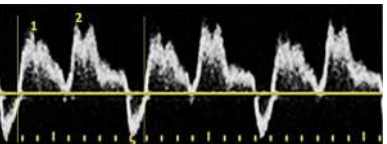

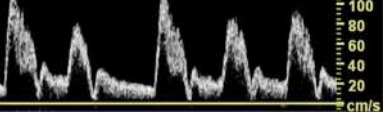
CCA, common carotid artery; ECA, external carotid artery; EDV, end-diastolic velocity; ICA, internal carotid artery; PSV, peak systolic velocity.

(Continued)

**Table 11.** (Continued)

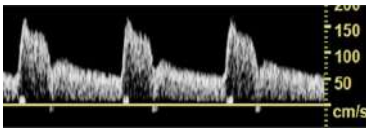
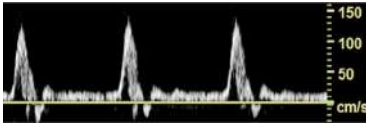
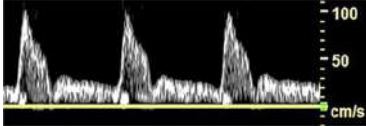
Pathophysiologic state and explanation	Waveform figure
<p><b>Vertebral artery pre-steal</b> Early in the development of a subclavian steal, a mid-systolic velocity deceleration is noted in the vertebral artery waveform. This feature becomes more prominent as the subclavian artery stenosis progresses and eventually results in a period of reverse flow (see <i>partial steal</i> below).</p>	
<p><b>Vertebral artery steal (partial)</b> Alternating forward and reverse flow direction are noted during each cardiac cycle, indicating a partial or 'incomplete' steal. The extent of steal (partial or complete) depends primarily on pressure gradients produced by the innominate or subclavian artery lesion.</p>	
<p><b>Vertebral artery steal (complete)</b> This vertebral artery waveform shows a complete steal with reverse flow direction throughout the cardiac cycle.</p>	

**Table 12.** Abnormal carotid waveforms associated with cardiac disease.

Pathophysiologic state and explanation	Waveform figure
<p><b>Aortic valve stenosis</b> Waveform changes are most evident in the CCA and ICA. The result is a dampened waveform.</p>	
<p><b>Aortic valve insufficiency</b> Waveform changes are most evident in the CCA and ICA. The result is reduced or retrograde diastolic flow.</p>	
<p><b>Aortic valve insufficiency</b> Aortic valve insufficiency may result in a bisferious pulse with two peaks evident in systole. The two peaks are separated by a mid-systolic retraction. The second peak is typically the same or greater than the first peak. Reversed diastolic flow may also be present.</p>	
<p><b>Aortic valve stenosis and insufficiency</b> Waveform changes are most evident in the CCA and ICA. The result is a prolonged upstroke with dampened peak and reduced or retrograde diastolic flow.</p>	
<p><b>Intra-aortic balloon pump</b> CCA waveforms demonstrate two systolic peaks: the first is due to the patient's own ventricular contraction (1) and the second due to inflation of the device balloon (2). Deflation of the balloon produces a brief reversal of flow in diastole (3).</p>	
<p><b>Left ventricular assist device</b> These ICA waveforms display lower PSV and increased EDV. Depending on the device settings, greater decreases in pulsatility can be observed.</p>	
<p><b>Arrhythmia</b> This CCA waveform displays irregularly spaced waveform cycles with varying PSV. Observed patterns will differ depending on the type of arrhythmia.</p>	

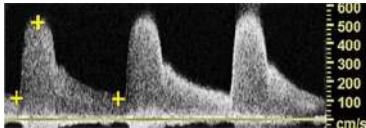
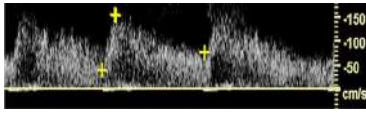
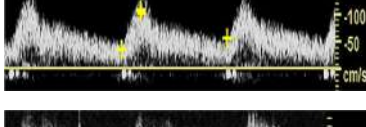
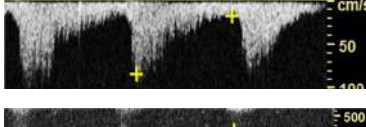
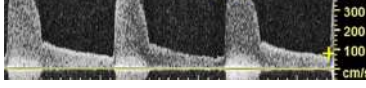
CCA, common carotid artery; EDV, end-diastolic velocity; ICA, internal carotid artery; PSV, peak systolic velocity.

**Table 13.** Normal mesenteric artery waveforms.

Physiologic state and explanation	Waveform figure
<p><b>Normal celiac (fasting or postprandial)</b> The liver and spleen have high metabolic demands, which are met by constant forward flow throughout systole and diastole.<sup>43-45</sup> The normal celiac artery Doppler waveform is antegrade, low resistive, and monophasic.</p>	
<p><b>Normal SMA (fasting)</b> Waveform is antegrade, high resistive, and multiphasic, with early diastolic flow reversal often apparent.<sup>43-45</sup></p>	
<p><b>Normal SMA (postprandial)</b> Velocity increases in both systole and diastole. Flow direction remains antegrade, but waveform becomes low resistive and monophasic.<sup>33,34,45,46</sup></p>	

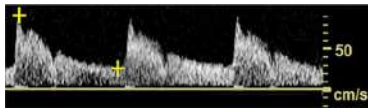
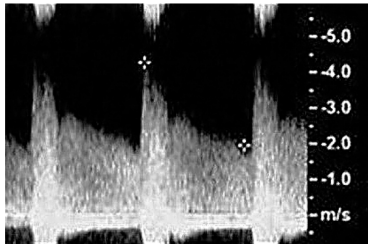
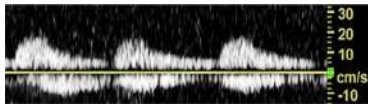
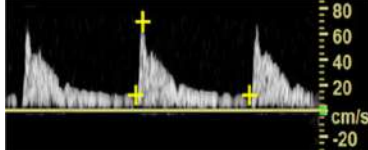
SMA, superior mesenteric artery.

**Table 14.** Abnormal mesenteric artery waveforms.

Pathophysiologic state and explanation	Waveform figure
<p><b>&gt; 70% Celiac stenosis</b> Flow-limiting (&gt; 70% diameter) celiac stenosis has a PSV exceeding 200 cm/sec<sup>33,46</sup> and an EDV in excess of 55 cm/sec.<sup>47,48</sup> The Doppler waveform remains antegrade, low resistive, and monophasic.</p>	
<p><b>Celiac immediately distal to stenosis</b> The PSV deteriorates, spectral broadening is present, but the flow direction and pattern remain antegrade, low resistive, and monophasic.</p>	
<p><b>Celiac downstream from flow-reducing stenosis</b> Distally, the velocity deteriorates further but the flow pattern becomes more laminar. The Doppler waveform remains antegrade, low resistive, and monophasic.</p>	
<p><b>Occluded celiac</b> Flow to the liver and spleen is maintained via the gastroduodenal and common hepatic arteries when the celiac trunk is occluded. Flow in these collaterals is retrograde, low resistive, and monophasic.</p>	
<p><b>&gt; 70% SMA stenosis</b> PSV &gt; 275/sec<sup>44</sup> and EDV &gt; 45 cm/sec.<sup>47</sup> Waveform remains antegrade, low resistive, and monophasic.</p>	


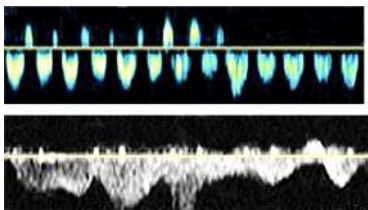
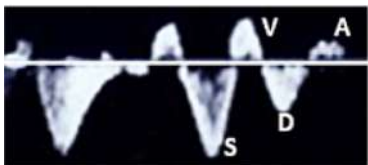
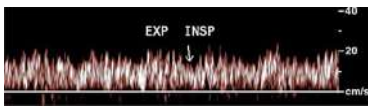
EDV, end-diastolic velocity; PSV, peak systolic velocity; SMA, superior mesenteric artery.

**Table 15.** Normal and abnormal renal artery waveforms.

Physiologic state and explanation	Waveform figure
<p><b>Normal renal artery</b> Flow in the normal main and/or accessory renal artery is antegrade, low resistive, and monophasic.</p>	
<p>Pathophysiologic state and explanation</p> <p>&gt; <b>60% Renal stenosis</b> Waveform remains antegrade, low resistive, and monophasic in the absence of distal renal artery stenosis or intrinsic renal parenchymal disease. The velocities shown here are &gt; 180 cm/sec, a commonly used criterion for renal artery stenosis.<sup>49</sup></p>	
<p><b>Renal downstream from flow-reducing stenosis</b> Antegrade, prolonged upstroke, low resistive, and monophasic with low PSV.</p>	
<p><b>Intrinsic renal parenchymal dysfunction</b> (Medical renal disease) Decreasing diastolic flow, antegrade, high resistive, and either monophasic or multiphasic.</p>	

PSV, peak systolic velocity.

**Table 16.** Normal mesenteric, renal, hepatic, and portal vein waveforms.

Physiologic state and explanation	Waveform figure
<p><b>Mesenteric veins: respirophasic</b> Owing to its distance from the heart, respirophasic flow typically is seen in the mesenteric veins.</p>	
<p><b>Renal vein</b> <i>Proximal aspect of the vein:</i> owing to its closer proximity to the heart, pulsatile flow is commonly seen. <i>Distal aspect of the vein:</i> often, a respirophasic waveform pattern is seen without pulsatility.</p>	
<p><b>Hepatic vein: pulsatile flow</b> This demonstrates two antegrade (i.e., S and D) waves and two retrograde (i.e., V and A) waves. The S-wave reflects rapid RA filling in early and mid-systole. The D-wave reflects rapid RA filling in early diastole. The V-wave reflects overfilling of RA at the end of ventricular systole. The A-wave reflects brief reversal of flow with RA contraction.<sup>50,51</sup></p>	
<p><b>Portal vein: hepatopetal flow</b> Antegrade flow towards the liver is characterized by low-velocity mild respiratory and moderate pulsatile variation. This occurs due to hepatic venous flow transmitted back to the portal vein through hepatic sinusoids.<sup>52</sup></p>	

RA, right atrium.

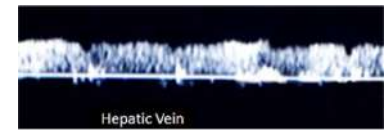
**Table 17.** Abnormal mesenteric, renal hepatic, and portal vein waveforms.

Pathophysiologic state and explanation

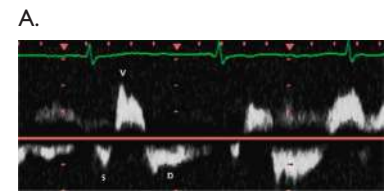
Waveform figure

**Pathological hepatic vein**

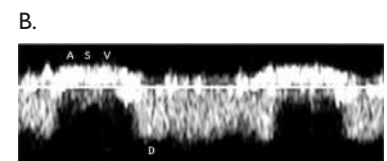
Alteration in hepatic vein flow and its characteristic waveforms may be seen with various cardiac, and hepatic and vascular conditions.



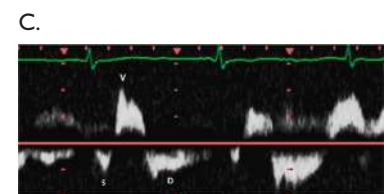
Diminished or lack of phasicity with reversed flow (hepatopetal) is seen with more central obstruction or compression (A).



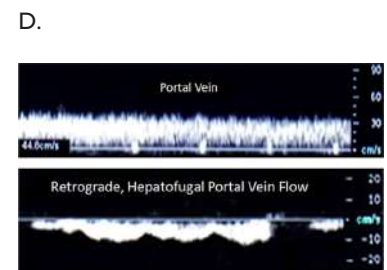
Prominent V-wave and diminished S-wave may be seen in TR and RVD (B). D-wave is often greater than S-wave.



Loss of the antegrade S-wave with formation of an ASV-wave complex in severe TR may lead to an oscillating pulsatile flow pattern (C).



Prominent A-wave and diminished D-wave may be seen with tricuspid stenosis and restricted atrial filling (D).



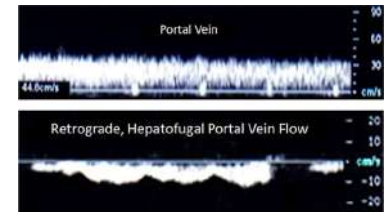
Diminished or absent A-wave may be seen in atrial fibrillation and liver parenchymal disease.

**Abnormal portal vein**

Portal hypertension causes blunting of the respiratory variation followed by development of bidirectional flow then overt retrograde flow that is away from the liver and termed hepatofugal.

RVD and/or TR-prominent pulsatile flow is noted.

TIPS results in alteration in flow direction with retrograde flow in the right and left portal vein and antegrade flow within the main portal vein.



RVD, right ventricle dysfunction; TR, tricuspid regurgitation; TIPS, transjugular intrahepatic portosystemic shunt.

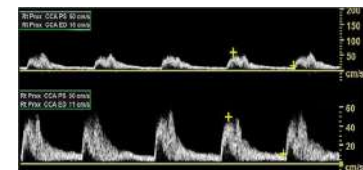
**Table 18.** Doppler waveform optimization.

Doppler parameters and artifacts

Waveform figure

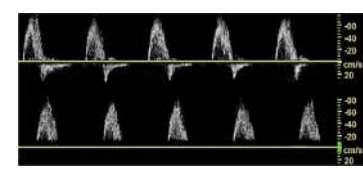
**PRF or scale**

Waveform should span half to three-quarters in height of available space for reporting velocity. Smaller waveforms can obscure nuanced findings in waveform morphology. A high-velocity scale setting may only display high-amplitude velocities, and low-amplitude velocities may be recognized as noise.



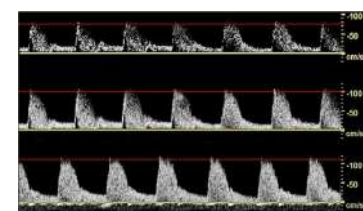
**Wall filter**

High-frequency band pass filters filter out low-frequency Doppler shifts produced from vessel wall motion and surrounding tissues (*motion artifact, noise, or cluster*). High settings could exclude vital waveform information (e.g. low-frequency shifts, loss of diastolic flow reversal, or appear as a floating waveform above the baseline). Lowering the filter setting will rectify these issues.



**Gain**

Proper gain setting enhances spectral Doppler envelope and window. Low gain settings can eliminate valuable waveform characteristics. High-gain settings can produce artifactual spectral broadening that can lead to overestimation of PSV and EDV.



EDV, end-diastolic velocity; PRF, pulse repetition frequency; PSV, peak systolic velocity.

(Continued)

**Table 18.** (Continued)

## Doppler parameters and artifacts

**Aliasing artifact**

Spectral aliasing occurs when the sample speed exceeds the velocity scale. If the Doppler scale (PRF) is too low, the spectral display 'wraps around', producing an appearance of reversed flow direction. This can be rectified by raising the velocity scale (PRF), lowering the spectral baseline, or using a lower frequency ultrasound transducer.

**Doppler gate (sample volume) size and location**

A large Doppler gate width (> 3.5 mm) or eccentric placement of the gate (adjacent to the wall) leads to spurious spectral broadening. This can be corrected with placement of the spectral gate to the center with a width of  $\leq 2$  mm.

**CW Doppler transducer angulation**

The optimal CW Doppler transducer-to-vessel angle of insonation typically lies closer to 45°. Off-axis or perpendicular angles will significantly attenuate the waveform, admit venous artifact from an adjacent vein, or inaccurately display the waveform as reversed flow.

**CW Doppler chart recorder speed**

Normal peripheral artery systolic waveform acceleration time is approximately 0.20 sec. Modifying the chart recorder speeds to slower than 25 cm/sec can alter the waveform appearance.

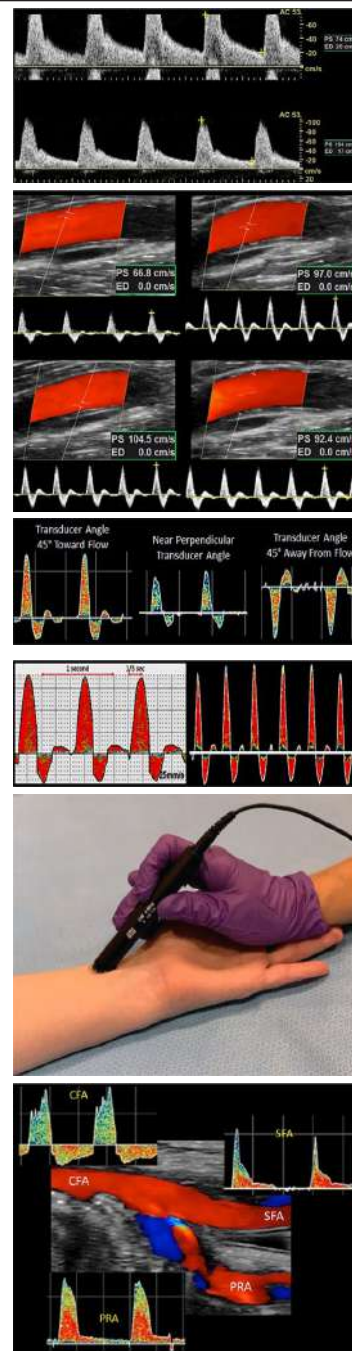
**CW Doppler transducer support**

Without support, the CW pencil probe becomes less stable, difficult to angulate and subject to motion artifact, particularly when used for evaluation of the posterior tibial and dorsalis pedis arteries. Waveform contour can be altered if the transducer is not properly braced and careful attention given to probe position to prevent off-axis or perpendicular transducer-to-vessel angles of insonation.

**CW misidentification of CFA**

Variations in anatomy can lead to incorrect identification of the SFA or PRA as the CFA. To avoid this error, shift the transducer medially and laterally; if a second arterial signal is encountered, then the Doppler probe is below the CFA and within the SFA and PRA confluence. The Doppler probe should be positioned more proximally to obtain the correct CFA sample location.

## Waveform figure



CCA, common carotid artery; CFA, common femoral artery; CW, continuous wave; PRA, profunda artery; PRF, pulse repetition frequency.

**Declaration of conflicting interests**

The authors declared the following potential conflicts of interest with respect to the research, authorship, and/or publication of this article: Patricia Poe is a consultant for Philips Ultrasound. No other authors have any potential conflicts of interest to declare.

**Funding**

The authors received no financial support for the research, authorship, and/or publication of this article.

**Supplementary material**

The supplementary material is available online with the article.

**References**

1. Benjamin EJ, Blaha MJ, Chiuve SE, et al.; American Heart Association Statistics Committee; Stroke Statistics Subcommittee. Heart disease and stroke statistics—2017 update: A report from the American Heart Association. *Circulation* 2017; 135: e146–e603.

2. Aronow WS. Peripheral arterial disease of the lower extremities. *Arch Med Sci* 2012; 8: 375–388.
3. Christiansen SC, Cannegieter SC, Koster T, et al. Thrombophilia, clinical factors, and recurrent venous thrombotic events. *JAMA* 2005; 293: 2352–2361.
4. Beebe-Dimmer JL, Pfeifer JR, Engle JS, et al. The epidemiology of chronic venous insufficiency and varicose veins. *Ann Epidemiol* 2005; 15: 175–184.
5. Scissons RP, Comerota A. Confusion of peripheral arterial Doppler waveform terminology. *J Diagn Med Sonogr* 2009; 25: 185–194.
6. Omarjee L, Stivalet O, Hoffmann C, et al. Heterogeneity of Doppler waveform description is decreased with the use of a dedicated classification. *Vasa* 2018; 47: 471–474.
7. Scissons RP. Characterizing triphasic, biphasic, and monophasic Doppler waveforms: Should a simple task be so difficult? *J Diagn Med Sonogr* 2008; 24: 269–276.
8. Beach KW. D. Eugene Strandness, Jr, MD, and the revolution in noninvasive vascular diagnosis: Part 1: Foundations. *J Ultrasound Med* 2005; 24: 259–272.
9. Strandness DE Jr, Schultz RD, Sumner DS, et al. Ultrasonic flow detection. A useful technic in the evaluation of peripheral vascular disease. *Am J Surg* 1967; 113: 311–320.
10. Beach KW. Waveform morphology. *UVMFLOWNET Archives* 2006; <https://list.uvm.edu/cgi-bin/wa?A2=ind0611&L=UVMFLOWNET&P=R8395>. Accessed 24 June 2020.
11. Fell G, Phillips DJ, Chikos PM, et al. Ultrasonic duplex scanning for disease of the carotid artery. *Circulation* 1981; 64: 1191–1195.
12. Nicolaides AN, Yao JST. *Investigation of vascular disorders*. Edinburgh: Churchill Livingstone, 1981.
13. Mahe G, Boulon C, Desormais I, et al. Statement for Doppler waveforms analysis. *Vasa* 2017; 46: 337–345.
14. Wen C, Gao M, Fu Y, et al. A high variability of arterial Doppler waveform descriptions exists in China. *Vasc Med* 2020; 25: 221–222.
15. Shaalan WE, French-Sherry E, Castilla M, et al. Reliability of common femoral artery hemodynamics in assessing the severity of aortoiliac inflow disease. *J Vasc Surg* 2003; 37: 960–969.
16. *Strandness's duplex scanning in vascular disorders*. 4th ed. Philadelphia, PA: Lippincott Williams & Wilkins, 2010.
17. Kupper C, Young L, Keagy B, et al. Spectral analysis of the femoral artery for identification of iliac artery lesions. *Bruit* 1984; 8: 157–163.
18. Barnes RW, Wilson MR. Doppler ultrasonic evaluation of peripheral arterial disease: A programmed audiovisual instruction [sound recording]. *Audovisual Center, University of Iowa, USA*, 1976: Cit no. 7901155A.
19. Sensier Y, Bell PR, London NJ. The ability of qualitative assessment of the common femoral Doppler waveform to screen for significant aortoiliac disease. *Eur J Vasc Endovasc Surg* 1998; 15: 357–364.
20. Zierler RE, Sumner DS. *Physiologic assessment of peripheral arterial occlusive disease*. Philadelphia, PA: Elsevier, 2005.
21. Baur GM, Zupan TL, Gates KH, et al. Blood flow in the common femoral artery. Evaluation in a vascular laboratory. *Am J Surg* 1983; 145: 585–588.
22. Jager KA, Phillips DJ, Martin RL, et al. Noninvasive mapping of lower limb arterial lesions. *Ultrasound Med Biol* 1985; 11: 515–521.
23. Labropoulos N, Tassiopoulos A. *Noninvasive diagnostic evaluation of peripheral arterial disease*. Totowa, NJ: Humana Press, 2005.
24. Zupan TL, Gates KH, Porter JM, et al. Evaluation of common femoral artery hemodynamics. *Bruit* 1983; 7: 45–49.
25. Yao JS, Nicolaides A. *Transcutaneous Doppler ultrasound in the management of lower limb ischemia*. New York: Churchill Livingstone, 1981.
26. Zierler RE. *Arterial duplex scanning*. Philadelphia, PA: WB Saunders, 1995.
27. Polak JF. *The peripheral arteries*. St Louis, MO: Williams & Wilkins, 2005.
28. Parks Medical Electronics, Inc. Operating manual, Parks Vascular Mini-Lab, Model 1050-C. October 2006.
29. Scissons RP, Neumyer M. The vascular waveform study results. *J Vasc Ultrasound* 2015; 39: 151–158.
30. Oates C. *Haemodynamics and Doppler waveforms explained*. Cambridge: Cambridge University Press, 2001.
31. Zygmunt J, Pichot O, Dauplaise T. *Practical guide to scanning, including the deep, small saphenous vein and great saphenous vein*. Boca Raton, FL: CRC Press, Taylor & Francis Group LLC, 2013.
32. Dawson DL, Beals H. *Acute lower extremity deep vein thrombosis*. Philadelphia, PA: Lippincott, Williams and Wilkins, 2010.
33. Moneta GL, Taylor DC, Helton WS, et al. Duplex ultrasound measurement of postprandial intestinal blood flow: Effect of meal composition. *Gastroenterology* 1988; 95: 1294–1301.
34. Pellerito JS, Revzin MV, Tsang JC. Doppler sonographic criteria for the diagnosis of inferior mesenteric artery stenosis. *J Ultrasound Med* 2009; 28: 641–650.
35. AbuRahma AF, Scott Dean L. Duplex ultrasound interpretation criteria for inferior mesenteric arteries. *Vascular* 2012; 20: 145–149.
36. Rose SC. Noninvasive vascular laboratory for evaluation of peripheral arterial occlusive disease: Part II—Clinical applications: Chronic, usually atherosclerotic, lower extremity ischemia. *J Vasc Interv Radiol* 2000; 11: 1257–1275.
37. Shabani Varaki E, Gargiulo GD, Penkala S, et al. Peripheral vascular disease assessment in the lower limb: A review of current and emerging non-invasive diagnostic methods. *Biomed Eng Online* 2018; 17: 61.
38. Scissons RP. Controversies in the interpretation of Doppler waveforms. *J Vasc Ultrasound* 2011; 35: 1–3.
39. Spronk S, den Hoed PT, de Jonge LC, et al. Value of the duplex waveform at the common femoral artery for diagnosing obstructive aortoiliac disease. *J Vasc Surg* 2005; 42: 236–242; discussion 242.
40. Burnham SJ, Jaques P, Burnham CB. Noninvasive detection of iliac artery stenosis in the presence of superficial femoral artery obstruction. *J Vasc Surg* 1992; 16: 445–451; discussion 452.
41. Gerhard-Herman M, Gardin JM, Jaff M, et al.; American Society of Echocardiography; Society for Vascular Medicine and Biology. Guidelines for noninvasive vascular laboratory testing: A report from the American Society of Echocardiography and the Society for Vascular Medicine and Biology. *Vasc Med* 2006; 11: 183–200.
42. Grant EG, Benson CB, Moneta GL, et al. Carotid artery stenosis: Gray-scale and Doppler US diagnosis—Society of Radiologists in Ultrasound Consensus Conference. *Radiology* 2003; 229: 340–346.
43. Lewis BD, James EM. Current applications of duplex and color Doppler ultrasound imaging: Abdomen. *Mayo Clin Proc* 1989; 64: 1158–1169.
44. Moneta GL, Yeager RA, Dalman R, et al. Duplex ultrasound criteria for diagnosis of splanchnic artery stenosis or occlusion. *J Vasc Surg* 1991; 14: 511–518; discussion 518–520.

45. Healy DA, Neumyer MM, Atnip RG, et al. Evaluation of celiac mesenteric vascular disease with duplex ultrasonography. *J Ultrasound Med* 1992; 11: 481–485.
46. Moneta GL, Lee RW, Yeager RA, et al. Mesenteric duplex scanning: A blinded prospective study. *J Vasc Surg* 1993; 17: 79–84; discussion 85–86.
47. Bowersox JC, Zwolak RM, Walsh DB, et al. Duplex ultrasonography in the diagnosis of celiac and mesenteric artery occlusive disease. *J Vasc Surg* 1991; 14: 780–786; discussion 786–788.
48. Zwolak RM, Fillinger MF, Walsh DB, et al. Mesenteric and celiac duplex scanning: A validation study. *J Vasc Surg* 1998; 27: 1078–1087; discussion 1088.
49. Granata A, Fiorini F, Andrulli S, et al. Doppler ultrasound and renal artery stenosis: An overview. *J Ultrasound* 2009; 12: 133–143.
50. Mittal SR. Doppler evaluation of hepatic vein flow. *Journal of the Indian Academy of Echocardiography and Cardiovascular Imaging* 2018; 2: 53–66.
51. Scoutt LM, Revzin MV, Thorisson H, et al. Ultrasound evaluation of the portal and hepatic veins. In: Zierler RE, Dawson DL (eds) *Strandness's duplex scanning in vascular disorders*. 5th ed. Philadelphia, PA: Lippincott Williams & Wilkins, 2016, pp.287–338.
52. McNaughton DA, Abu-Yousef MM. Doppler US of the liver made simple. *Radiographics* 2011; 31: 161–188.