

JAMA Cardiology | Review

# Clinical Characteristics and Pharmacological Management of COVID-19 Vaccine-Induced Immune Thrombotic Thrombocytopenia With Cerebral Venous Sinus Thrombosis

## A Review

John G. Rizk, RPh, MSc; Aashish Gupta, MD; Partha Sardar, MD; Brandon Michael Henry, MD; John C. Lewin, MD; Giuseppe Lippi, MD; Carl J. Lavie, MD

**IMPORTANCE** The COVID-19 pandemic saw one of the fastest developments of vaccines in an effort to combat an out-of-control pandemic. The 2 most common COVID-19 vaccine platforms currently in use, messenger RNA (mRNA) and adenovirus vector, were developed on the basis of previous research in use of this technology. Postauthorization surveillance of COVID-19 vaccines has identified safety signals, including unusual cases of thrombocytopenia with thrombosis reported in recipients of adenoviral vector vaccines. One of the devastating manifestations of this syndrome, termed *vaccine-induced immune thrombotic thrombocytopenia* (VITT), is cerebral venous sinus thrombosis (CVST). This review summarizes the current evidence and indications regarding biology, clinical characteristics, and pharmacological management of VITT with CVST.

**OBSERVATIONS** VITT appears to be similar to heparin-induced thrombocytopenia (HIT), with both disorders associated with thrombocytopenia, thrombosis, and presence of autoantibodies to platelet factor 4 (PF4). Unlike VITT, HIT is triggered by recent exposure to heparin. Owing to similarities between these 2 conditions and lack of high-quality evidence, interim recommendations suggest avoiding heparin and heparin analogues in patients with VITT. Based on initial reports, female sex and age younger than 60 years were identified as possible risk factors for VITT. Treatment consists of therapeutic anticoagulation with nonheparin anticoagulants and prevention of formation of autoantibody-PF4 complexes, the latter being achieved by administration of high-dose intravenous immunoglobulin (IVIG). Steroids, which can theoretically inhibit the production of new antibodies, have been used in combination with IVIG. In severe cases, plasma exchange should be used for clearing autoantibodies. Monoclonal antibodies, such as rituximab and eculizumab, can be considered when other therapies fail. Routine platelet transfusions, aspirin, and warfarin should be avoided because of the possibility of worsening thrombosis and magnifying bleeding risk.

**CONCLUSIONS AND RELEVANCE** Adverse events like VITT, while uncommon, have been described despite vaccination remaining the most essential component in the fight against the COVID-19 pandemic. While it seems logical to consider the use of types of vaccines (eg, mRNA-based administration) in individuals at high risk, treatment should consist of therapeutic anticoagulation mostly with nonheparin products and IVIG.

JAMA Cardiol. doi:10.1001/jamacardio.2021.3444  
Published online August 10, 2021.

**Author Affiliations:** Arizona State University, Edson College, Phoenix, Arizona (Rizk); John Ochsner Heart and Vascular Institute, Ochsner Clinical School—The University of Queensland School of Medicine, New Orleans, Louisiana (Gupta, Sardar, Lavie); The Heart Institute, Cincinnati Children's Hospital Medical Center, Cincinnati, Ohio (Henry); National Coalition on Health Care, Washington, DC (Lewin); Section of Clinical Biochemistry, University of Verona, Verona, Italy (Lippi).

**Corresponding Author:** John G. Rizk, RPh, MSc, Arizona State University, Edson College, 550 N 3rd St, Phoenix, AZ 85004 (john.rizk@asu.edu).

**T**he COVID-19 pandemic is challenging the global public health and health care sectors in many ways. The public health, health care, and related supply chain infrastructures were unprepared and underfunded for this crisis. Perhaps the most impressive and timely response to COVID-19 has been the unprecedentedly rapid production of effective vaccines against this infectious disease, while effective therapeutics and cost-effective diagnostics have lagged.<sup>1</sup>

Cerebral venous sinus thrombosis (CVST) is a rare form of cerebrovascular disease that typically affects young women of child-bearing age<sup>2-4</sup> and is generally thought to be associated with the same general risk factors as other more common forms of venous thrombosis, such as pregnancy; medications, including oral contraceptives and chemotherapy; infections of brain, ears, or face; head trauma; inherited blood clotting disorders (eg, functional deficiencies of coagulation protein S or C, antithrombin, and factor V Leiden); and, rarely, thrombocytopenia,<sup>5,6</sup> with prevalence of prothrombotic disorders being especially high in adolescents.<sup>7</sup> COVID-19 infection has itself a rare but demonstrated association with CVST. A retrospective analysis<sup>8</sup> identified a CVST incidence of 39.0 patients per million (95% CI, 25.2-60.2) after COVID-19 infection compared with the 2-week period before COVID-19 infection (0.4 per million). Another retrospective study evaluated 14 483 patients diagnosed with COVID-19 infection over a period of 4 months and found a higher incidence of CVST (20 of 100 000 patients; 95% CI, 4 of 100 000 to 60 of 100 000).<sup>9</sup> However, CVST with thrombocytopenia was entirely unexpected as a much rarer complication associated with certain types of COVID-19 vaccination.

Two recent reports described case reviews with clinical and laboratory findings of thrombotic thrombocytopenia events after the AstraZeneca vaccine (ChAdOx1), 1 from Germany and Austria and 1 from Norway.<sup>10,11</sup> Many patients had platelet-activating antibodies directed against platelet factor 4 (PF4), resulting in a prothrombotic state and thrombocytopenia. This phenomenon was thought to resemble heparin-induced thrombocytopenia (HIT), but these individuals had not received heparin prior to developing clots. The antigenic target on PF4 also seems different between HIT and VITT, because the latter condition has been recently characterized as the development of anti-PF4 antibodies with 8 recognized surface amino acids located within the heparin binding site of the protein, different from those recognized by the anti-PF4 antibodies developing in patients with HIT.<sup>12</sup> The authors of these articles propose *vaccine-induced immune thrombotic thrombocytopenia* (VITT) as the name of this emerging syndrome. Similarly, See et al<sup>13</sup> reported on 12 individuals with CVST and thrombocytopenia, all of whom were women aged 18 to 60 years who developed these complications between 6 to 15 days postvaccination with the Johnson and Johnson vaccine (Ad26.COV2.S). Several other cases of this phenomenon have now been described all around the world.<sup>14</sup> That said, there has been tremendous scientific interest in, but also public concern regarding, CVST with VITT following COVID-19 vaccination, despite the risk of CVST from COVID-19 infection being 60- to 230-fold higher than the risk from vaccination.<sup>15</sup>

The ChAdOx1 vaccine is a chimpanzee adenoviral vector vaccine, whereas the Ad26.COV2.S vaccine is a human adenoviral vector vaccine.<sup>16,17</sup> The clinical syndrome seen after both of these vaccines appears similar; however, the extent to which these cases represent the same pathophysiologic syndrome is still unclear, and

the syndrome seems to occur at a 4-fold higher frequency with ChAdOx1.<sup>15</sup> In contrast, with the Pfizer-BioNTech messenger RNA (mRNA) vaccine (BNT162b2), there have been no reports of CVST following a large number of doses administered. As of April 12, 2021, 3 cases of CVST had been reported following 84.7 million administered doses of the Moderna mRNA-1273 vaccine, with all 3 individuals having normal platelet counts.<sup>18</sup> Only 1 report to date documents possible VITT after the second dose of the mRNA-1273 vaccine.<sup>19</sup>

Herein, we discuss the current evidence regarding pharmacological treatments, including anticoagulants, immunoglobulin therapy, steroids, and other molecules, in the management of VITT with CVST postvaccination, as well as the clinical characteristics and pathophysiology of this emerging disorder.

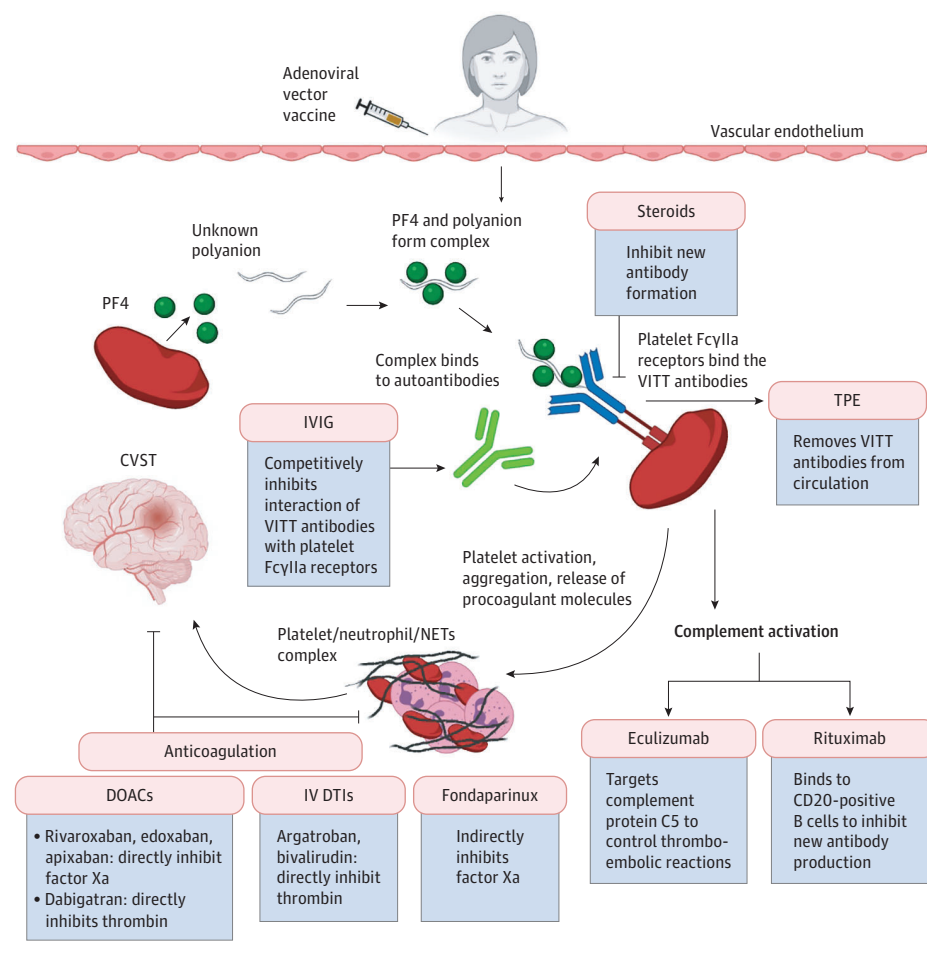
---

## Pathophysiology

VITT is atypical in that CVST and other forms of thrombotic events occur in association with thrombocytopenia (10 000 to 100 000 per microl). CVST occurs when thrombi form in the cerebral veins and major dural sinuses,<sup>20</sup> occurring in 3 to 4 people per million annually, much less common than venous thromboembolism, deep vein thrombosis, and pulmonary embolism, which are seen in 1 in 1000 people annually.<sup>21</sup> However, diagnosis of CVST is difficult, and these estimates are likely lower than the true incidence.<sup>22</sup> CVST is an uncommon disorder in the general population but can be more common in certain subpopulations. CVST causes symptoms by 2 main mechanisms that increase pressure in the brain<sup>20</sup>: (1) increased venular and capillary pressures and (2) decreased cerebrospinal fluid absorption. Impaired venous drainage causes brain tissue edema, impairing delivery of oxygenated blood and leading to ischemia. A rare yet severe manifestation of CVST is venous hemorrhage, which occurs when capillary walls become weakened. Four main clinical syndromes are seen with CVST<sup>6,20</sup>: (1) in 90% of patients, intracranial hypertension presenting as headache, which may be generalized or localized and worsens with position change; (2) in 44% of patients, focal deficits with hemiparesis and fluent aphasia; (3) seizures in 30% to 40% of patients, usually with venous hemorrhage; and (4) encephalopathy, often seen in elderly patients and those with major cerebral thrombosis. The average 30-day mortality is 6% and depends on the size of the thrombus, with the primary cause of death being herniation from large venous hemorrhage.<sup>23</sup> Most patients will have complete or partial recovery, while approximately 10% have permanent neurological deficits at 1-year follow-up. Recurrence of CVST is rare, occurring in 3% of patients. CVST may occur with venous thromboembolism, with most cases developing within the first year of CVST.<sup>24</sup>

In the pathophysiology of HIT, exposure to a polyanion, such as unfractionated heparin, results in complexes of PF4 and heparin.<sup>25</sup> PF4 is a positively charged protein found in platelet  $\alpha$ -granules that is released in plasma on platelet activation. When PF4 binds to heparin, the conformation of PF4 changes and a new antigen is exposed, which results in the development of IgG autoantibodies against this complex. The complex, now containing heparin, PF4, and autoantibodies, crosslinks many Fc $\gamma$ RIIa receptors on platelets, resulting in intracellular signaling, thromboxane biosynthesis, platelet activation, and aggregation. Activated platelets degranulate and release more PF4 molecules as well as procoagulant microparticles

**Figure 1. Schematic Representation of the Pathogenesis of Vaccine-Induced Immune Thrombotic Thrombocytopenia (VITT) and Therapeutic Targets**



Owing to lack of high-quality data, management recommendations are based on expert opinion and extrapolation from treatment of heparin-induced thrombocytopenia given similarities between these 2 conditions. Given the low incidence of VITT, randomized clinical trials comparing various treatment options may not be feasible and may not reach the required sample size. CVST indicates cerebral venous sinus thrombosis; DOAC, direct oral anticoagulants; DTI, direct thrombin inhibitors; IV, intravenous; IVIG, intravenous immunoglobulin; PF4, platelet factor-4; TPE, therapeutic plasma exchange.

in plasma, which are responsible for increased thrombin generation. In addition, HIT antibodies activate monocytes and endothelial cells leading to accelerated thrombin generation via expression of tissue factor. Neutrophil extracellular traps enhance coagulation by providing a scaffold for platelets, red blood cells, von Willebrand factor, and tissue factors. This positive feedback loop results in a hypercoagulable state and thrombosis. However, thrombocytopenia seen in HIT is predominantly due to removal of activated platelets and antibody-coated platelets by the macrophages of the reticulo-endothelial system.<sup>26</sup> In the case of VITT, autoantibodies are also generated, although these patients have not received heparin and it is likely that an unidentified polyanion in the adenoviral vaccines or expressed by the infected cells by the vaccine is binding to PF4. In patients with suspected or confirmed VITT, rapid initiation of treatment similar to that of severe HIT is hence recommended (Figure 1). Currently, to our knowledge, no potential strategies are available for the prevention of VITT.

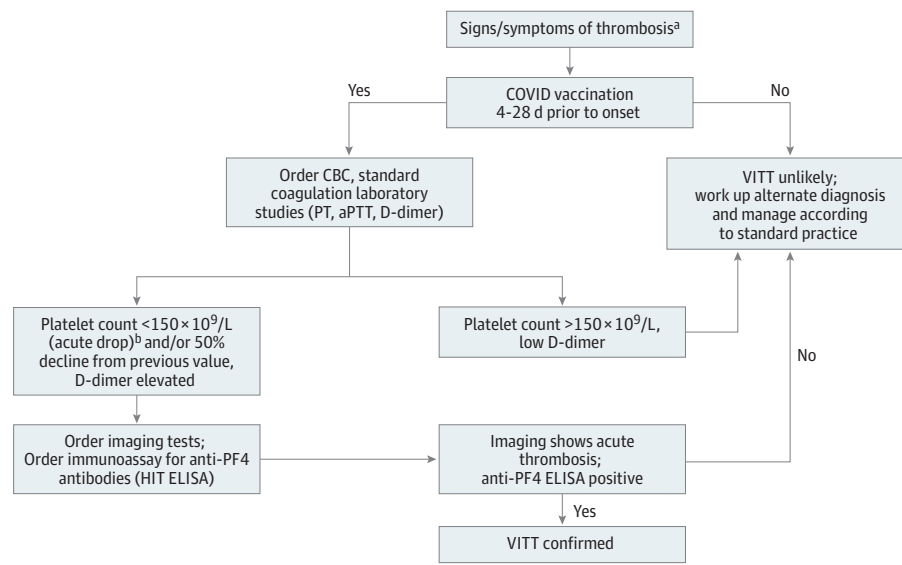
## Epidemiology and Clinical Characteristics of VITT

Based on studies in Europe and the United Kingdom, the incidence of VITT is around 1 per 100 000 to 250 000 vaccine recipients,

although this is a continuously moving target.<sup>27</sup> CVST is estimated to occur at a rate of 1 per 100 000 vaccine recipients with the ChAdOx1 vaccine and 1 per 1 000 000 with the Ad26.COVS vaccine.<sup>28</sup> More than 90% of patients with CVST have been younger than 60 years, with more women being affected than men (2.5:1 ratio).<sup>27</sup> In the US, all patients who received the Ad26.COVS vaccine and developed CVST with VITT were female.<sup>13</sup> The median (range) onset of symptoms was 10 (5-24) days after the ChAdOx1 vaccine<sup>10,11,29</sup> and 8 (6-15) days after the Ad26.COVS vaccine.<sup>13</sup> Notably, most patients did not have a history of coagulation disorders.<sup>30</sup> The most common thrombotic event associated with VITT is CVST, although patients have presented with other forms of thrombosis, especially venous thromboembolism, abdominal vein clots, and arterial clots.<sup>10,11,29</sup> A report from Scotland also revealed that the risk of arterial thrombosis may be increased by more than 20% in recipients of adenovirus-based vaccines.<sup>31</sup>

Patients presented with symptoms associated with increased intracranial pressure (eg, headaches, visual disturbances, nausea and/or vomiting, and other neurological symptoms) as well as shortness of breath, lethargy, back pain, abdominal pain, petechiae, and leg or arm weakness. Compared with other thrombotic events, this phenomenon is unique in that these patients had positive test results for HIT. Patients in the US, Europe, and UK all had positive test

Figure 2. Differential Diagnosis Algorithm for Vaccine-Induced Immune Thrombotic Thrombocytopenia (VITT)



If VITT is suspected, the following tests should be performed: complete blood cell count (CBC) with platelet count, heparin-induced thrombocytopenia (HIT) assays (anti-PF4–based enzyme-linked immunosorbent assay and functional platelet assays), along with measurement of plasma fibrinogen and D-dimer. Platelet count can be low to normal if VITT is detected early in the disease process. Enzyme-linked immunosorbent assays based on PF4–poly (vinyl sulfonate) can be used as rapid tests and appear to yield the lowest rate of false negative results. Direct imaging, such as computerized tomography venography or magnetic resonance venography, is used to diagnose cerebral

venous sinus thrombosis. aPTT indicates activated partial thromboplastin time; ELISA, enzyme-linked immunosorbent assay; PF4, platelet factor-4; PT, prothrombin time.

<sup>a</sup> Symptoms include persistent severe headache, vision change (blurred, double vision), seizures, chest pain, shortness of breath, abdominal pain, limb pain, and swelling.

<sup>b</sup> Using a cutoff of  $150 \times 10^3/\mu\text{L}$  for platelets leads to the highest sensitivity, although most patients with VITT present with values  $<50 \times 10^3/\mu\text{L}$ .

results for PF4 or heparin antibody immunoassay (PF4 enzyme-linked immunosorbent assay).<sup>32</sup> One peculiar aspect of this pathology is that positivity for anti-PF4 antibodies seems to be mostly restricted to enzyme-linked immunosorbent assay–based assays, with other methods being characterized by rather poor diagnostic sensitivity.<sup>33</sup> Platelet activation assays were positive in the Europe and United Kingdom groups, but serotonin release assays were not uniformly positive in the US. The variable positivity with serotonin release assays seems to be influenced by some technical aspects, in that assay modification by adding PF4 yields a much higher diagnostic sensitivity.<sup>34</sup> Platelet nadirs ranged from  $7$  to  $113 \times 10^3/\mu\text{L}$  (to convert to  $\times 10^9/\text{L}$ , multiply by 1) and  $10$  to  $127 \times 10^3/\mu\text{L}$  for the ChAdOx1 and Ad26.COV2.S vaccines, respectively. Reported plasma fibrinogen levels were low to normal (suggesting a component of intravascular coagulation), ranging between  $40$  and  $568$  mg/dL (to convert to g/L, multiply by 0.01). D-dimer levels were markedly elevated, several-fold higher than the upper limit of the reference range, reflecting a severe thrombotic event. Platelet recovery appears to occur with use of a nonheparin anticoagulant in addition to IVIG. The mortality rate can be as high as 50%, unless the syndrome is recognized early and appropriately treated.<sup>28,32</sup> A diagnostic algorithm is proposed in Figure 2.

## Risk Factors

There are no well-known risk factors for VITT with CVST postvaccination other than female sex and age younger than 60 years. In the

general population, CVST is much more common in women than men, with a ratio of approximately 3:1.<sup>35</sup> CVST has a higher frequency among patients younger than 40 years, those with thrombophilia, or women who are pregnant, post partum, or taking hormonal contraception.<sup>2,31</sup> Infections, including localized (eg, sinusitis and meningitis) and systemic (eg, COVID-19), and inflammatory diseases (eg, vasculitides, rheumatoid arthritis, and inflammatory bowel disease) may also contribute to the development of CVST. Other risk factors include cancer, high blood cell counts, trauma (eg, head trauma, neurosurgical procedure, and lumbar puncture), and nephrotic syndrome. Prior thrombosis is not currently considered a risk factor for VITT.

## First-line Therapies

### Anticoagulation

Therapeutic anticoagulation with nonheparin anticoagulants is the primary treatment for VITT with or without CVST. Owing to a high incidence of spontaneous intracerebral hemorrhage in patients with CVST, use of anticoagulation was a matter of debate for many years. However, current consensus is to treat CVST patients with or without preexisting intracerebral hemorrhage with therapeutic anticoagulation. This recommendation is based on pre-COVID-19 randomized clinical trials evaluating anticoagulation in patients with CVST, which showed that anticoagulation is not only important in managing CVST, but also does not lead to extension of hemorrhages.<sup>36,37</sup> These findings support the hypothesis that improvement in

**Box. Heparin-Containing Products to Be Avoided in Patients With Vaccine-Induced Immune Thrombotic Thrombocytopenia**

Unfractionated heparin

Low-molecular-weight heparin (eg, enoxaparin, dalteparin, nadroparin, tinzaparin)

Heparin lock flush solutions

Heparin-bonded catheters (eg, CVC, PAC)

Prothrombin complex concentrates (eg, 4F-PCC)<sup>a</sup>

Hematopoietic Progenitor Cells by Apheresis (HPC-A)

Abbreviations: CVC, central venous catheter; 4F-PCC, 4-factor prothrombin complex; PAC, pulmonary artery catheter.

<sup>a</sup> 3F-PCC can be used if the patient has a history of heparin-induced thrombocytopenia.

venous outflow obstruction with anticoagulation decreases venular and capillary pressure and reduces the risk of further bleeding.<sup>20</sup>

Society recommendations are to avoid heparin and heparin-containing products in the management of this syndrome (Box). Non-heparin anticoagulants are currently considered better therapeutic options, supported by case reports describing progression of thrombosis following heparin use<sup>10</sup> and the similarity of this complication to HIT and autoimmune HIT. Direct oral anticoagulants (DOACs), such as dabigatran, apixaban, rivaroxaban, edoxaban, and fondaparinux, as well as parenteral direct thrombin inhibitors (eg, bivalirudin and argatroban) are options, as these have been used in patients with HIT.<sup>38</sup> The decision between each of these agents will depend on the drug profile and patient situation (Table 1). DOACs and fondaparinux can be used in noncritically ill patients with less severe thrombocytopenia. However, there is a slight risk of cross-reactivity between fondaparinux and HIT antibodies.<sup>39</sup> In critically ill patients with severe thrombocytopenia (platelet level less than  $50 \times 10^3/\mu\text{L}$ ) and severe risk of bleeding, intravenous direct thrombin inhibitors can be used given their intravenous route and short half-life.<sup>40</sup> Parenteral direct thrombin inhibitors bear a considerable bleeding risk, lack reversal agents, and are associated with higher costs.<sup>41</sup> Yet their effects are rapidly reversed on discontinuation. VITT is considered provoked thrombosis, and treatment for at least 3 months is recommended.

DOACs are recommended over vitamin K antagonists, such as warfarin, for VITT, despite international guidelines for CVST suggesting vitamin K antagonists over DOACs, although other studies are evaluating DOACs in the context of CVST.<sup>20,42</sup> Warfarin can induce a paradoxical hypercoagulable state, commonly within 3 to 10 days of therapy initiation, owing to its inhibitory effects on some coagulation proteins. This is mostly because protein C and vitamin K-dependent natural anticoagulant have shorter half-lives than most other vitamin K-dependent  $\gamma$ -carboxylated procoagulants (factors II, IX, and X).<sup>43</sup> These effects are reported to be more profound in the hypercoagulable setting of HIT. Thus, in VITT, alternative anticoagulants should be administered, and warfarin therapy may be resumed when the platelet count has recovered (greater than  $150 \times 10^3/\mu\text{L}$  for at least 2 days).

The American Heart Association and American Stroke Association 2011 Scientific Statement for the management of CVST<sup>2</sup> recommends restricting catheter-directed fibrinolysis to experienced centers and patients whose condition deteriorates despite intensive coagulation. Systematic reviews have shown that fibrinolytic

treatment is associated with intracranial and extracranial major bleeding complications.<sup>44</sup> Thus, fibrinolytic therapy should only be considered in patients with extensive CVST whose condition worsens despite anticoagulation.<sup>45</sup>

**IVIg**

IVIg contains immunoglobulin G of all subclasses derived from pooled human plasma, and has been used in the management of COVID-19.<sup>46</sup> In high doses, IVIg can competitively inhibit the binding of VITT antibodies with the platelet Fc $\gamma$ RIIa, thereby inhibiting platelet activation and aggregation.<sup>47</sup> In autoimmune HIT and other diseases where IVIg can be considered, a dose of 1 g/kg daily for at least 2 days in divided doses can rapidly increase platelet counts and reduce hypercoagulability.<sup>47-49</sup> This outcome is particularly important in patients with VITT who manifest severe thrombocytopenia and thrombosis, with or without bleeding, and who require anticoagulation.<sup>50</sup> Case series have documented that IVIg improves platelet count and recovery in VITT by inhibition of serum-induced platelet activation.<sup>10,11,50</sup> Since platelet activation is likely the key step in the manifestation of VITT, several professional societies recommend administration of IVIg as soon as VITT is diagnosed or under consideration (Table 2),<sup>5,51-56</sup> although the usefulness of additional treatment with IVIg requires further study. It has been suggested that actual body weight should be used in dosing IVIg, given its dose-dependent effects in reducing antibody-induced platelet activation.<sup>47,50</sup> IVIg is also used in immune thrombocytopenic purpura; thus, IVIg can be administered prior to PF4 enzyme-linked immunosorbent assay results being available, when differential diagnosis of either VITT or immune thrombocytopenic purpura is still being considered.

Because IVIg may inhibit serotonin release in the serotonin release assays, blood samples should be drawn before IVIg infusion to avoid false negative results.<sup>57</sup> IVIg is itself potentially prothrombotic, and thrombotic events have been reported after IVIg administration in patients with immune thrombocytopenic purpura.<sup>58</sup>

**Steroids as Second-line Agents**

Steroids can hypothetically inhibit the synthesis of new autoantibodies, thereby interrupting platelet activation and thrombosis. To our knowledge, there are no large-scale studies documenting benefits with steroids in the treatment of HIT, and the available data are limited to isolated case reports and case series.<sup>59,60</sup> More recently, systemic steroids have been used in combination with IVIg for the management of VITT. Of the 5 individuals with VITT in the study by Schultz et al,<sup>11</sup> 4 were treated with concomitant methylprednisolone (1 mg/kg/d) and IVIg. Three patients had documented CVST and 2 of these patients died. George et al<sup>61</sup> reported successful treatment for a patient with VITT and CVST using steroids, IVIg, and bivalirudin.

**When Are Platelet and Fibrinogen Transfusions Indicated?**

Platelet transfusion may be considered in patients with VITT and serious bleeding, or prophylactically if invasive procedures with high bleeding risk are required. However, routine platelet transfusion

**Table 1. Summary of Nonheparin Anticoagulants for Use in Patients With Confirmed or Suspected Vaccine-Induced Immune Thrombotic Thrombocytopenia (VITT)**

Anticoagulant	Dose	Route of administration	Mode of action	Reversal agent	Monitoring	Drug interactions	Primary mechanism of elimination (half-life)	Contraindications	Special populations
Rivaroxaban	15 mg Twice daily with food for 3 wk, then 20 mg OD with food	Oral	Direct factor Xa inhibitor	Andexanet alfa	None; antifactor Xa activity can be monitored if required	Metabolized primarily by CYP3A4. P-gp substrate	Kidney (5-9 h)	Active pathological bleeding; severe hypersensitivity to rivaroxaban	Use in pregnancy and breastfeeding unknown
Edoxaban	60 mg Once daily	Oral	Direct factor Xa inhibitor	Andexanet alfa	None; antifactor Xa activity can be monitored if required	P-gp substrate	50% Kidney, 50% metabolism and biliary or intestinal excretion (10-14 h)	Active pathological bleeding	Use in pregnancy and breastfeeding unknown
Apixaban	10 mg Twice daily for 1 wk, then 5 mg twice daily	Oral	Direct factor Xa inhibitor	Andexanet alfa	None; antifactor Xa activity can be monitored if required	Metabolized primarily by CYP3A4. P-gp substrate	Hepatic (8-15 h)	Active pathological bleeding; severe hypersensitivity to apixaban	Use in pregnancy and breastfeeding unknown
Dabigatran	150 mg Twice daily	Oral	Direct thrombin inhibitor	Idarucizumab	Not recommended unless drug failure is suspected, major or life-threatening bleeding is experienced while taking dabigatran, or urgent surgery or invasive procedure is required while taking dabigatran	P-gp substrate	Kidney (12-17 h)	Active pathological bleeding; severe hypersensitivity to dabigatran	Use in pregnancy and breastfeeding unknown; risk of bleeding increases with age
Argatroban	2 µg/kg/min	Intravenous	Direct thrombin inhibitor	None	Adjust to aPTT 1.5-3 × baseline	Heparin, warfarin, thrombolytics, GPIs	Hepatobiliary (40-50 min)	Hypersensitivity to argatroban or to any component of the product; major bleeding	Can be used in pregnancy; use in breastfeeding unknown
Bivalirudin	0.15 mg/kg/h	Intravenous	Direct thrombin inhibitor	None	Adjust to aPTT 1.5-2.5 × baseline	Heparin, warfarin, thrombolytics, GPIs	Enzymatic (25 min)	Active major bleeding; hypersensitivity to bivalirudin or its components	Can be used in pregnancy; use in breastfeeding unknown; possible increased bleeding risk in elderly individuals
Fondaparinux	Weight-based: <50 kg, 5 mg once daily; 50-100 kg, 7.5 mg once daily; >100 kg, 10 mg once daily	Subcutaneous	Indirect factor Xa inhibitor	Andexanet alfa	None; antifactor Xa activity can be monitored if needed	No major interactions	Kidney (17-24 h)	Active major bleeding; history of serious hypersensitivity, severe kidney impairment (CrCl <30 mL/min), thrombocytopenia associated with positive in vitro test for antiplatelet antibody in the presence of fondaparinux, bacterial endocarditis	Can be used in pregnancy; use with caution with elderly individuals

Abbreviations: CrCl, creatinine clearance; GPI, glycoprotein IIb/IIIa inhibitors.

should be avoided.<sup>51,53</sup> It has been reported that in patients with HIT, platelet transfusions led to a 5-fold increase in mortality.<sup>62</sup> Platelets are the source of PF4, the antigenic target for the antibodies

in VITT, and may thus worsen progression of VITT. However, a notable difference in clinical presentation of HIT and VITT is the incidence of bleeding. Concomitant bleeding, which is relatively

**Table 2. Current Societal Recommendations for Treatment of Confirmed or Suspected Vaccine-Induced Immune Thrombotic Thrombocytopenia (VITT)**

Therapy	American Society of Hematology (ASH) <sup>51</sup>	American Heart Association and American Stroke Association <sup>5</sup>	International Society on Thrombosis and Hemostasis <sup>52</sup>	British Society for Haematology <sup>53</sup>	Thrombosis & Hemostasis Society of Australia and New Zealand <sup>54</sup>	Ontario COVID-19 Science Advisory Table <sup>55</sup>	Society of Thrombosis and Hemostasis Research <sup>56</sup>
<b>Anticoagulants</b>							
Direct thrombin inhibitors	Yes	Yes	Yes	Yes, critical illness dose argatroban appropriate while platelet count $<30 \times 10^3/\mu\text{L}^a$	Yes	Alternative	Yes
DOACs	Yes	Yes	Yes	Yes	Yes	Yes, first line	Yes
Fondaparinux	Yes	Yes	Yes	Yes, low-dose fondaparinux appropriate while platelet count $<30 \times 10^3/\mu\text{L}^a$	Yes	Not described	Not recommended (may foster production of platelet-activating antibodies)
<b>Other therapies</b>							
IVIG	Recommended (with anticoagulation), 1 g/kg daily for 2 d	Recommended; 1 g/kg body weight daily for 2 d after laboratory testing for PF4 antibodies has been sent	Early IVIG recommended, 0.5-1 g/kg daily for 2 d	Early IVIG recommended, 1g/kg divided into 2 d if needed; may be repeated	Consider for possible VITT, give immediately for probable VITT, 1-2 g/kg in 2 divided doses	Recommended; 1 g/kg daily for at least 2 d (use actual body weight)	Recommended (with anticoagulation), 1 g/kg daily on 2 consecutive days
Platelet transfusion	Not recommended; only if initial treatment fails or if patient has serious bleeding, and/or needs surgical intervention	Avoid	Avoid, unless patient requires urgent surgery	If urgent neurosurgery required	Avoid	Avoid	Not described
Steroids	No consensus or data yet available	Considered	Considered (eg, prednisone 1 to 2 mg/kg) if platelet count is less than $50 \times 10^3/\mu\text{L}^a$	Benefit may outweigh risk, but uncertain	If signs of new or progressive thrombosis	Not described	Not described
TPE	Not recommended, unless thrombosis continues despite anticoagulation and IVIG	Not described	Consider early use if platelet count remains less than $30 \times 10^3/\mu\text{L}^a$ despite IVIG and steroid treatment	Considered if very severe or treatment-resistant disease	If signs of new or progressive thrombosis	Not described	Not described
Rituximab	Not described	Not described	Not described	If IVIG and TPE unsuccessful	Not described	Not described	Not described
Eculizumab	Described	Not described	Not described	Not described	Not described	Not described	Not described

Abbreviations: DOAC, direct oral anticoagulants; IVIG, intravenous immunoglobulin; TPE, therapeutic plasma exchange.

<sup>a</sup> To convert to  $10^9/\text{L}$ , multiply by 1.

uncommon in HIT, tends to occur more often in patients with VITT and CVST and portends a poor prognosis. In the case series in Europe, all 4 patients with VITT and CVST experienced an intracerebral hemorrhage. Likewise, among the 12 individuals with CVST and VITT in the study in the US, 7 had intracerebral hemorrhage.<sup>11</sup> In the population-based study in Scotland, the frequency of hemorrhagic events up to nearly 1 month after vaccination was increased by approximately 50%.<sup>31</sup>

Platelet transfusion also may be required prior to neurosurgical procedures in these patients. A concern with platelet transfusion is increased risk of thrombosis, and additional thrombotic events after receiving platelet transfusion were reported.<sup>29</sup> In addition, a large retrospective review of 6332 patients with HIT found higher odds of arterial thrombosis but not venous thrombosis (age- and

sex-adjusted odds ratio, 3.4; 95% CI, 1.2-9.5) as well as mortality (age- and sex-adjusted odds ratio, 5.2; 95% CI, 2.6-10.5) in patients who received platelet transfusion.<sup>62</sup>

Human fibrinogen (coagulation factor I) plays an important role in normal hemostasis and binds platelets and thrombin, resulting in platelet aggregation and promoting coagulation. Fibrinogen concentrate and cryoprecipitate are prepared from pooled human plasma and are used in fibrinogen deficiency with clinically significant bleeding or prior to invasive procedures. Low fibrinogen levels (less than 1.5 g/L) can be seen in severe cases of HIT with consumptive coagulopathy.<sup>63</sup> Low fibrinogen levels have been reported in approximately half of the cases of VITT.<sup>10,11,13</sup> The incidence of low fibrinogen levels may be different if patients are identified earlier in the disease course.

## Avoiding Aspirin

Aspirin is an irreversible inhibitor of platelet cyclooxygenases and prevents formation of prostaglandin derivative, thromboxane A<sub>2</sub>, thereby inhibiting platelet aggregation. In vitro studies have not shown any efficacy of aspirin in inhibiting PF4 antibody mediated platelet activation.<sup>64,65</sup> Owing to an increased risk of bleeding and no clear benefit, aspirin should be probably avoided in patients with VITT. For the same reasons, aspirin as a prophylaxis for VITT in vaccine recipients is not recommended.<sup>66</sup> This is different for COVID-19, where aspirin could be considered prophylactically for systemic microthrombosis.<sup>67</sup> Similarly, other antiplatelet agents like P2Y<sub>12</sub> inhibitors (eg, clopidogrel) should be avoided for both prophylaxis and treatment for VITT, and there are no data supporting their use.

## Plasma Exchange

Therapeutic plasma exchange (TPE), or plasmapheresis, is an extracorporeal therapy to exchange a patient's plasma and large molecular weight substances, such as autoantibodies, with replacement fluid (eg, donor plasma, albumin, or a combination of albumin and saline). TPE has been recommended prior to administration of heparin for urgent cardiac surgery as a way to quickly remove HIT antibodies.<sup>68</sup> However, routine use of plasma exchange for treatment of VITT is not currently recommended.<sup>51</sup> Besides the bleeding risk posed with placement of a large bore catheter in a patient with thrombocytopenia and need for prolonged apheresis, rapid or complete removal of IgG antibodies might not be possible owing to the large extravascular volume of distribution.<sup>51</sup> However, in patients with CVST, severe (extensive thrombosis with platelets less than 30 ×10<sup>3</sup>/μL) or resistant (continued thrombosis despite IVIG) VITT treatment with IVIG alone might not be enough because of the high antibody burden. In these circumstances, it is recommended to start daily TPE early,<sup>69</sup> which should be continued for 5 days or longer until appropriate increase in platelet count is observed.<sup>51-53</sup>

## Other Investigational Therapies

### Rituximab

The benefit of rituximab in various autoimmune disorders is believed to be due to decreased production of pathogenic autoantibodies resulting from depletion of nonmalignant B cells.<sup>70</sup> Schell

et al<sup>71</sup> reported a case of refractory HIT that failed to respond to non-heparin anticoagulation and TPE. This prompted a second course of TPE combined with immunosuppression using corticosteroids and rituximab in an attempt to inhibit new antibody production. It is unclear if this approach was effective, as the patient's platelet count improved only after bilateral limb amputation due to gangrene, with the authors contemplating infection as a possible contributor. Theoretically, rituximab can be effective, although currently there are no reports on the use or efficacy of rituximab in this condition.

### Eculizumab

The complement system is a group of plasma proteins that form an essential part in the innate immune system, and complement activation may contribute to immune-complex–driven thromboinflammation in autoimmune diseases.<sup>72</sup> Fc receptor–dependent platelet activation, addressed by IVIG, is not the only mechanism by which VITT develops. PF4 and anti-PF4 immune complexes can also activate the complement system through the classical pathway, which is activated by an antigen-antibody reaction.<sup>73</sup>

Eculizumab, a long-acting humanized monoclonal antibody targeted against complement C5, prevents the cleavage of C5 into C5a and C5b by the enzyme C5 convertase.<sup>74</sup> Therapeutic complement modulation may offer clinical benefits for patients with VITT,<sup>75</sup> particularly in patients for whom IVIG does not work. In a case series by Tiede et al,<sup>75</sup> eculizumab was given to 2 patients, one with CVST and thrombotic microangiopathy and the other with splanchnic vein thrombosis for whom IVIG and anticoagulation therapy (ie, salvage therapy) did not work. Both patients improved following therapy, suggesting a possible role for complement inhibition in patients whose condition progresses despite other therapies.

## Conclusions

VITT, while uncommon, is a clinically devastating and fatal complication after vaccination with adenoviral vector COVID-19 vaccines. The mechanism of development of the prothrombotic state and its association with the vaccine are still only partially known, because multiple converging prothrombotic pathways may be involved in the pathogenesis. The primary treatment option is therapeutic anticoagulation with nonheparin products and IVIG. It is reasonable to avoid adenoviral vector COVID-19 vaccines in high-risk populations, especially younger female individuals, and instead consider immunization with an mRNA-based vaccine.

### ARTICLE INFORMATION

**Accepted for Publication:** July 19, 2021.

**Published Online:** August 10, 2021.  
doi:10.1001/jamacardio.2021.3444

**Author Contributions:** Drs Rizk and Gupta had full access to all of the data in the study and take responsibility for the integrity of the data and the accuracy of the data analysis.

**Concept and design:** Rizk, Gupta, Sardar, Henry, Lippi, Lavie.

**Acquisition, analysis, or interpretation of data:** Rizk, Gupta, Henry, Lewin, Lippi, Lavie.

**Drafting of the manuscript:** Rizk, Gupta, Sardar, Lewin, Lavie.

**Critical revision of the manuscript for important intellectual content:** All authors.

**Administrative, technical, or material support:** Sardar, Lavie.

**Supervision:** Rizk.

**Conflict of Interest Disclosures:** None reported.

### REFERENCES

- Rizk JG, Forthal DN, Kalantar-Zadeh K, et al. Expanded Access Programs, compassionate drug use, and Emergency Use Authorizations during the

COVID-19 pandemic. *Drug Discov Today*. 2021;26(2):593-603. doi:10.1016/j.drudis.2020.11.025

- Saposnik G, Barinagarrementeria F, Brown RD Jr, et al; American Heart Association Stroke Council and the Council on Epidemiology and Prevention. Diagnosis and management of cerebral venous thrombosis: a statement for healthcare professionals from the American Heart Association/American Stroke Association. *Stroke*. 2011;42(4):1158-1192. doi:10.1161/STR.Ob013e31820a8364

- Ferro JM, Aguiar de Sousa D. Cerebral venous thrombosis: an update. *Curr Neurol Neurosci Rep*. 2019;19(10):74. doi:10.1007/s11910-019-0988-x

4. Silvis SM, Aguiar de Sousa D, Ferro JM, Coutinho JM. Cerebral venous thrombosis. *Nat Rev Neurol*. 2017;13(9):555-565. doi:10.1038/nrneuro.2017.104
5. Furie KL, Cushman M, Elkind MSV, Lyden PD, Saposnik G; American Heart Association/American Stroke Association Stroke Council Leadership. Diagnosis and management of cerebral venous sinus thrombosis with vaccine-induced immune thrombotic thrombocytopenia. *Stroke*. 2021;52(7):2478-2482. doi:10.1161/STROKEAHA.121.035564
6. Idiculla PS, Gurala D, Palanisamy M, Vijayakumar R, Dhandapani S, Nagarajan E. Cerebral venous thrombosis: a comprehensive review. *Eur Neurol*. 2020;83(4):369-379. doi:10.1159/000509802
7. Sèbire G, Tabarki B, Saunders DE, et al. Cerebral venous sinus thrombosis in children: risk factors, presentation, diagnosis and outcome. *Brain*. 2005;128(Pt 3):477-489. doi:10.1093/brain/awh412
8. Taquet M, Husain M, Geddes JR, Luciano S, Harrison PJ. Cerebral venous thrombosis and portal vein thrombosis: a retrospective cohort study of 537, 913 COVID-19 cases. *medRxiv* 2021.04.27.21256153. doi:10.1101/2021.04.27.21256153
9. Siegler JE, Cardona P, Arenillas JF, et al. Cerebrovascular events and outcomes in hospitalized patients with COVID-19: the SVIN COVID-19 Multinational Registry. *Int J Stroke*. 2021;16(4):437-447. doi:10.1177/1747493020959216
10. Greinacher A, Thiele T, Warkentin TE, Weisser K, Kyrle PA, Eichinger S. Thrombotic thrombocytopenia after ChAdOx1 nCov-19 vaccination. *N Engl J Med*. 2021;384(22):2092-2101. doi:10.1056/NEJMoa2104840
11. Schultz NH, Sørvoll IH, Michelsen AE, et al. Thrombosis and thrombocytopenia after ChAdOx1 nCov-19 vaccination. *N Engl J Med*. 2021;384(22):2124-2130. doi:10.1056/NEJMoa2104882
12. Huynh A, Kelton JG, Arnold DM, Daka M, Nazy I. Antibody epitopes in vaccine-induced immune thrombotic thrombocytopenia. *Nature*. Published online July 7, 2021. doi:10.1038/s41586-021-03744-4
13. See I, Su JR, Lale A, et al. US Case Reports of Cerebral Venous Sinus Thrombosis With Thrombocytopenia After Ad26.COV2.S Vaccination, March 2 to April 21, 2021. *JAMA*. 2021;325(24):2448-2456. doi:10.1001/jama.2021.7517
14. Long B, Bridwell R, Gottlieb M. Thrombosis with thrombocytopenia syndrome associated with COVID-19 vaccines. *Am J Emerg Med*. 2021;49:58-61. doi:10.1016/j.ajem.2021.05.054
15. Bikkdeli B, Chatterjee S, Arora S, et al. Cerebral venous sinus thrombosis in the US population, after adenovirus-based SARS-CoV-2 vaccination, and after COVID-19. *J Am Coll Cardiol*. 2021;78(4):408-411. doi:10.1016/j.jacc.2021.06.001
16. Marsh GA, McAuley AJ, Au GG, et al. ChAdOx1 nCov-19 (AZD1222) vaccine candidate significantly reduces SARS-CoV-2 shedding in ferrets. *NPJ Vaccines*. 2021;6(1):67. doi:10.1038/s41541-021-00315-6
17. Livingston EH, Malani PN, Creech CB. The Johnson & Johnson Vaccine for COVID-19. *JAMA*. 2021;325(15):1575. doi:10.1001/jama.2021.2927
18. Shimabukuro T; CDC COVID-19 Vaccine Task Force Vaccine Safety Team. Reports of cerebral venous sinus thrombosis with thrombocytopenia after Janssen COVID-19 vaccine. National Center for Immunization & Respiratory Diseases. Accessed June 28, 2021. <https://www.cdc.gov/vaccines/acip/meetings/downloads/slides-2021-04-23/03-COVID-Shimabukuro-508.pdf>
19. Sangli S, Virani A, Cheronis N, et al. Thrombosis with thrombocytopenia after the messenger RNA-1273 vaccine. *Ann Intern Med*. 2021;L21-L0244. doi:10.7326/L21-0244
20. Piazza G. Cerebral venous thrombosis. *Circulation*. 2012;125(13):1704-1709. doi:10.1161/CIRCULATIONAHA.111.067835
21. Cushman M. Epidemiology and risk factors for venous thrombosis. *Semin Hematol*. 2007;44(2):62-69. doi:10.1053/j.seminhematol.2007.02.004
22. Ferro JM, Lopes MG, Rosas MJ, Fontes J; VENOPORT Investigators. Delay in hospital admission of patients with cerebral vein and dural sinus thrombosis. *Cerebrovasc Dis*. 2005;19(3):152-156. doi:10.1159/000083248
23. Dentali F, Gianni M, Crowther MA, Ageno W. Natural history of cerebral vein thrombosis: a systematic review. *Blood*. 2006;108(4):1129-1134. doi:10.1182/blood-2005-12-4795
24. Miranda B, Ferro JM, Canhão P, et al; ISCVT Investigators. Venous thromboembolic events after cerebral vein thrombosis. *Stroke*. 2010;41(9):1901-1906. doi:10.1161/STROKEAHA.110.581223
25. Hogan M, Berger JS. Heparin-induced thrombocytopenia (HIT): Review of incidence, diagnosis, and management. *Vasc Med*. 2020;25(2):160-173. doi:10.1177/1358863X19898253
26. Chong BH. Heparin-induced thrombocytopenia. *J Thromb Haemost*. 2003;1(7):1471-1478. doi:10.1046/j.1538-7836.2003.00270.x
27. Centers for Disease Control and Prevention. Advisory Committee on Immunization Practice (ACIP) ACIP Presentation Slides. Accessed June 14, 2021. <https://www.cdc.gov/vaccines/acip/meetings/slides-2021-04-23.html>.
28. Ropper AH, Klein JP. Cerebral venous thrombosis. *N Engl J Med*. 2021;385(1):59-64. doi:10.1056/NEJMra2106545
29. Scully M, Singh D, Lown R, et al. Pathologic antibodies to platelet factor 4 after ChAdOx1 nCov-19 vaccination. *N Engl J Med*. 2021;384(23):2202-2211. doi:10.1056/NEJMoa2105385
30. Gupta A, Sardar P, Cash ME, Milani RV, Lavie CJ. Covid-19 vaccine-induced thrombosis and thrombocytopenia—a commentary on an important and practical clinical dilemma. *Prog Cardiovasc Dis*. 2021;50(3):0620(21)00050-5. Published online May 18, 2021. doi:10.1016/j.pcad.2021.05.001
31. Simpson CR, Shi T, Vasileiou E, et al. First-dose ChAdOx1 and BNT162b2 COVID-19 vaccines and thrombocytopenic, thromboembolic and hemorrhagic events in Scotland. *Nat Med*. 2021;27(7):1290-1297. doi:10.1038/s41591-021-01408-4
32. Cines DB, Bussell JB. SARS-CoV-2 vaccine-induced immune thrombotic thrombocytopenia. *N Engl J Med*. 2021;384(23):2254-2256. doi:10.1056/NEJMe2106315
33. Vayne C, Rollin J, Gruel Y, et al. PF4 Immunoassays in vaccine-induced thrombotic thrombocytopenia. *N Engl J Med*. 2021;c2106383. doi:10.1056/NEJMc2106383
34. Favaloro EJ. Laboratory testing for suspected COVID-19 vaccine-induced (immune) thrombotic thrombocytopenia. *Int J Lab Hematol*. Published online June 17, 2021. doi:10.1111/ijlh.13629
35. Coutinho JM, Ferro JM, Canhão P, et al. Cerebral venous and sinus thrombosis in women. *Stroke*. 2009;40(7):2356-2361. doi:10.1161/STROKEAHA.108.543884
36. Einhäupl KM, Villringer A, Meister W, et al. Heparin treatment in sinus venous thrombosis. *Lancet*. 1991;338(8767):597-600. doi:10.1016/0140-6736(91)90607-Q
37. de Bruijn SFTM, Stam J. Randomized, placebo-controlled trial of anticoagulant treatment with low-molecular-weight heparin for cerebral sinus thrombosis. *Stroke*. 1999;30(3):484-488. doi:10.1161/01.STR.30.3.484
38. Warkentin TE, Pai M, Linkins LA. Direct oral anticoagulants for treatment of HIT: update of Hamilton experience and literature review. *Blood*. 2017;130(9):1104-1113. doi:10.1182/blood-2017-04-778993
39. Spinler SA. New concepts in heparin-induced thrombocytopenia: diagnosis and management. *J Thromb Thrombolysis*. 2006;21(1):17-21. doi:10.1007/s11239-006-5571-z
40. Burstein B, Wieruszewski PM, Zhao Y-J, Smischney N. Anticoagulation with direct thrombin inhibitors during extracorporeal membrane oxygenation. *World J Crit Care Med*. 2019;8(6):87-98. doi:10.5492/wjccm.v8.i6.87
41. Rizk J, Mehra MR. Anticoagulation management strategies in heart transplantation. *Prog Cardiovasc Dis*. 2020;63(3):210-218. doi:10.1016/j.pcad.2020.02.002
42. Ulivi L, Squitieri M, Cohen H, Cowley P, Werring DJ. Cerebral venous thrombosis: a practical guide. *Pract Neurol*. 2020;20(5):356-367. doi:10.1136/practneurol-2019-002415
43. Srinivasan AF, Rice L, Bartholomew JR, et al. Warfarin-induced skin necrosis and venous limb gangrene in the setting of heparin-induced thrombocytopenia. *Arch Intern Med*. 2004;164(1):66-70. doi:10.1001/archinte.164.1.66
44. Dentali F, Squizzato A, Gianni M, et al. Safety of thrombolysis in cerebral venous thrombosis: a systematic review of the literature. *Thromb Haemost*. 2010;104(5):1055-1062. doi:10.1160/TH10-05-0311
45. Canhão P, Falcão F, Ferro JM. Thrombolytics for cerebral sinus thrombosis: a systematic review. *Cerebrovasc Dis*. 2003;15(3):159-166. doi:10.1159/000068833
46. Rizk JG, Kalantar-Zadeh K, Mehra MR, Lavie CJ, Rizk Y, Forthal DN. Pharmac-immunomodulatory therapy in COVID-19. *Drugs*. 2020;80(13):1267-1292. doi:10.1007/s40265-020-01367-z
47. Warkentin TE. High-dose intravenous immunoglobulin for the treatment and prevention of heparin-induced thrombocytopenia: a review. *Expert Rev Hematol*. 2019;12(8):685-698. doi:10.1080/17474086.2019.1636645
48. Park BD, Kumar M, Nagalla S, et al. Intravenous immunoglobulin as an adjunct therapy in persisting heparin-induced thrombocytopenia. *Transfus Apher Sci*. 2018;57(4):561-565. doi:10.1016/j.transci.2018.06.007
49. Hwang SR, Wang Y, Weil EL, Padmanabhan A, Warkentin TE, Pruthi RK. Cerebral venous sinus

thrombosis associated with spontaneous heparin-induced thrombocytopenia syndrome after total knee arthroplasty. *Platelets*. 2020;1-5. doi:10.1080/09537104.2020.1828574

50. Bourguignon A, Arnold DM, Warkentin TE, et al. Adjunct immune globulin for vaccine-induced thrombotic thrombocytopenia. *N Engl J Med*. Published online June 9, 2021. doi:10.1056/NEJMoa2107051

51. American Society of Hematology. Thrombosis with thrombocytopenia syndrome (also termed vaccine-induced thrombotic thrombocytopenia). Accessed June 17, 2021. <https://www.hematology.org/covid-19/vaccine-induced-immune-thrombotic-thrombocytopenia>

52. International Society on Thrombosis and Haemostasis. Interim guidance for the diagnosis and treatment on vaccine-induced immune thrombotic thrombocytopenia. Accessed June 17, 2021. [https://cdn.ymaws.com/www.isth.org/resource/resmgr/ISTH\\_VITT\\_Guidance\\_2.pdf](https://cdn.ymaws.com/www.isth.org/resource/resmgr/ISTH_VITT_Guidance_2.pdf)

53. Pavord J, Lester W, Makris M, Scully M, Hunt B. Guidance from the Expert Haematology Panel (EHP) on COVID-19 vaccine-induced immune thrombocytopenia and thrombosis (VITT). Accessed June 17, 2021. <https://b-s-h.org.uk/media/19718/guidance-v20-20210528-002.pdf>

54. Thrombosis and Haemostasis Society of Australia and New Zealand. Suspected vaccine induced immune thrombotic thrombocytopenia (VITT). Accessed June 17, 2021. <https://www.thanz.org.au/documents/item/591>

55. Table S. COVID-19 Advisory for Ontario. Vaccine-Induced Immune Thrombotic Thrombocytopenia (VITT) Following Adenovirus Vector COVID-19 Vaccination. Accessed June 17, 2021. <https://covid19-sciencetable.ca/sciencebrief/vaccine-induced-immune-thrombotic-thrombocytopenia-vitt-following-adenovirus-vector-covid-19-vaccination/>

56. Oldenburg J, Klamroth R, Langer F, et al. Diagnosis and management of vaccine-related thrombosis following AstraZeneca COVID-19 vaccination: guidance statement from the GTH. *Hamostaseologie*. 2021;41(3):184-189. doi:10.1055/a-1469-7481

57. Padmanabhan A, Jones CG, Pechauer SM, et al. IVIg for treatment of severe refractory

heparin-induced thrombocytopenia. *Chest*. 2017; 152(3):478-485. doi:10.1016/j.chest.2017.03.050

58. Woodruff RK, Grigg AP, Firkin FC, Smith IL. Fatal thrombotic events during treatment of autoimmune thrombocytopenia with intravenous immunoglobulin in elderly patients. *Lancet*. 1986;2(8500):217-218. doi:10.1016/S0140-6736(86)92511-0

59. Doucette K, DeStefano CB, Jain NA, Cruz AL, Malkovska V, Fitzpatrick K. Treatment of refractory delayed onset heparin-induced thrombocytopenia after thoracic endovascular aortic repair with intravenous immunoglobulin (IVIg). *Res Pract Thromb Haemost*. 2017;1(1):134-137. doi:10.1002/rth2.12009

60. Gonzales M, Pipalia A, Weil A. Refractory heparin-induced thrombocytopenia with cerebral venous sinus thrombosis treated with IVIg, steroids, and a combination of anticoagulants: a case report. *J Investig Med High Impact Case Rep*. 2019;7:2324709619832324. doi:10.1177/2324709619832324

61. George G, Friedman KD, Curtis BR, Lind SE. Successful treatment of thrombotic thrombocytopenia with cerebral sinus venous thrombosis following Ad26.COV2.S vaccination. *Am J Hematol*. 2021;96(8):E301-E303. doi:10.1002/ajh.26237

62. Goel R, Ness PM, Takemoto CM, Krishnamurti L, King KE, Tobian AAR. Platelet transfusions in platelet consumptive disorders are associated with arterial thrombosis and in-hospital mortality. *Blood*. 2015;125(9):1470-1476. doi:10.1182/blood-2014-10-605493

63. Greinacher A, Selleng K, Warkentin TE. Autoimmune heparin-induced thrombocytopenia. *J Thromb Haemost*. 2017;15(11):2099-2114. doi:10.1111/jth.13813

64. Brieger DB, Mak KH, Kottke-Marchant K, Topol EJ. Heparin-induced thrombocytopenia. *J Am Coll Cardiol*. 1998;31(7):1449-1459. doi:10.1016/S0735-1097(98)00134-X

65. Polgár J, Eichler P, Greinacher A, Clemetson KJ. Adenosine diphosphate (ADP) and ADP receptor play a major role in platelet activation/aggregation induced by sera from heparin-induced thrombocytopenia patients. *Blood*. 1998;91(2):549-554. doi:10.1182/blood.V91.2.549

66. Public Health England. Information for healthcare professionals on blood clotting following

COVID-19 vaccination. Accessed June 16, 2021. <https://www.gov.uk/government/publications/covid-19-vaccination-blood-clotting-information-for-healthcare-professionals/information-for-healthcare-professionals-on-blood-clotting-following-covid-19-vaccination>.

67. Rizk JG, Lavie CJ, Gupta A. Low-dose aspirin for early COVID-19: does the early bird catch the worm? *Expert Opin Investig Drugs*. 2021;1-4:1-4. doi:10.1080/13543784.2021.1950687

68. Welsby IJ, Um J, Milano CA, Ortel TL, Arepally G. Plasmapheresis and heparin reexposure as a management strategy for cardiac surgical patients with heparin-induced thrombocytopenia. *Anesth Analg*. 2010;110(1):30-35. doi:10.1213/ANE.Ob013e3181c3c1cd

69. Patriquin CJ, Laroche V, Selby R, et al. Therapeutic plasma exchange in vaccine-induced immune thrombotic thrombocytopenia. *N Engl J Med*. Published online July 7, 2021. doi:10.1056/NEJMc2109465

70. Cambridge G, Leandro MJ, Edwards JCW, et al. Serologic changes following B lymphocyte depletion therapy for rheumatoid arthritis. *Arthritis Rheum*. 2003;48(8):2146-2154. doi:10.1002/art.11181

71. Schell AM, Petras M, Szczepiorkowski ZM, Ornstein DL. Refractory heparin induced thrombocytopenia with thrombosis (HITT) treated with therapeutic plasma exchange and rituximab as adjuvant therapy. *Transfus Apher Sci*. 2013;49(2):185-188. doi:10.1016/j.transci.2013.01.007

72. Mastellos DC, Skendros P, Lambris JD. Is complement the culprit behind COVID-19 vaccine-related adverse reactions? *J Clin Invest*. 2021;131(11):151092. doi:10.1172/JCI151092

73. James K. Complement: activation, consequences, and control. *Am J Med Technol*. 1982;48(9):735-742.

74. Patriquin CJ, Kuo KHM. Eculizumab and beyond: the past, present, and future of complement therapeutics. *Transfus Med Rev*. 2019; 33(4):256-265. doi:10.1016/j.tmr.2019.09.004

75. Tiede A, Sachs UJ, Czwalinna A, et al. Prothrombotic immune thrombocytopenia after COVID-19 vaccine. *Blood*. Published online April 28, 2021. doi:10.1182/blood.2021011958