

REVIEW

Guraminder Singh Thind, MD

Department of Critical Care Medicine, Respiratory Institute, Cleveland Clinic, Cleveland, OH

Steven Fox, MD

Department of Critical Care Medicine, Respiratory Institute, Cleveland Clinic, Cleveland, OH

Mohit Gupta, MD

Department of Hospital Medicine, Cleveland Clinic, Cleveland, OH; Clinical Assistant Professor, Cleveland Clinic Lerner College of Medicine of Case Western Reserve University, Cleveland, OH

Praveen Chahar, MD

Anesthesiology Institute, Cleveland Clinic, Cleveland, OH; Clinical Assistant Professor, Cleveland Clinic Lerner College of Medicine of Case Western Reserve University, Cleveland, OH

Robert Jones, DO, FACEP

Department of Emergency Medicine, Metro-Health Medical Center, Cleveland, OH; Professor, Cleveland Clinic Lerner College of Medicine of Case Western Reserve University, Cleveland, OH

Siddharth Dugar, MD

Department of Critical Care Medicine, Respiratory Institute, Cleveland Clinic, Cleveland, OH; Clinical Assistant Professor, Cleveland Clinic Lerner College of Medicine of Case Western Reserve University, Cleveland, OH

Point-of-care ultrasonography for the hospitalist

ABSTRACT

Point-of-care ultrasonography (POCUS) has emerged as a vital tool in medicine. Initially used for procedural guidance, POCUS is now used for diagnostics and monitoring of the lung, heart, abdomen, and deep vein thrombosis. This wide applicability makes it an essential tool for hospitalists in daily clinical practice. This article provides an overview of the clinical integration of POCUS and basic image interpretation.

KEY POINTS

Lung POCUS can help in evaluating pneumothorax, alveolar-interstitial syndrome, lung consolidation, and pleural effusions as the cause for respiratory distress.

Focused cardiac ultrasonography can help in evaluating left and right ventricular function, right atrial pressure, pericardial effusion, and tamponade.

Abdominal ultrasonography can aid evaluation of ascites, hemoperitoneum, hydronephrosis, acute pyelonephritis, and gallstones, and can confirm Foley catheter placement.

Point-of-care compression ultrasonography can rapidly detect deep vein thrombosis with high accuracy.

POCUS can guide numerous procedures, including central venous catheter insertion, peripheral intravenous catheter insertion, abdominal paracentesis, and thoracentesis.

HOSPITALISTS ARE INCREASINGLY USING point-of-care ultrasonography (POCUS), and have access to ultrasound machines that are more portable, more available, and less expensive. The numerous uses of POCUS for procedural guidance, diagnosis, and monitoring can add considerable value to patient care.

All hospitalists should have an understanding of POCUS nomenclature, applications, and findings. This review highlights various uses of POCUS in hospitalized patients.

■ DIRECT CLINICIAN INVOLVEMENT

Ultrasonography is low-cost, radiation-free, and noninvasive, allowing it to be repeated multiple times with little risk to patients. What sets it apart from traditional diagnostic ultrasonography is that it is wholly performed by a bedside clinician directly involved in patient care, without requiring a sonographer and radiologist for image acquisition and interpretation (Table 1). A hospitalist can quickly perform a physical examination combined with goal-directed ultrasonography of various organs based on presenting signs and symptoms. Serial scans can be performed to assess progression or response to therapy.

POCUS enhances patient experience and patient-clinician rapport by increasing interactions between the clinician and patient.¹ POCUS has become notably important in the COVID-19 pandemic, allowing protocolized ultrasonographic assessment of multiple organs by a bedside physician, thereby minimizing exposure and the need for formal studies.²

Recognizing the importance of POCUS, numerous medical schools have integrated training in ultrasonography in their curricula.

doi:10.3949/cjcm.88a.20141

TABLE 1

Point-of-care ultrasonography workflow compared with traditional consultative ultrasonography

	Consultative ultrasonography	POCUS
Decision to perform ultrasonography	Primary clinician	Primary clinician
Image acquisition	Sonographer	
Image interpretation	Sonographer Radiologist	
Clinical integration	Radiologist Primary clinician	

The Society of Hospital Medicine, the American College of Physicians, and the Alliance for Academic Internal Medicine, have also endorsed its use.³⁻⁵

Billing for ultrasound-assisted procedures may provide a means to offset the costs of equipment, training, and administration.

IMPROPER USE AND INTERPRETATION CAN CAUSE HARM

POCUS can improve patient care but may also cause harm through improper use and interpretation.⁶ It needs to be applied in a deliberate and thoughtful manner: multiple views should be obtained for appropriate interpretation, and images must be evaluated in the clinical context. A comprehensive imaging study should be considered if POCUS was of limited utility and the probability of a particular disorder remains high despite negative findings with POCUS.

The accuracy of POCUS depends on the skills and judgment of the operator. Even if basic findings are understood, many nuances and potential pitfalls exist. Clinicians may be falsely reassured by seemingly normal POCUS findings while the patient actually has a serious disease that a radiologic study could detect. Conversely, incidental findings may lead to unnecessary treatments and testing.

But because POCUS may be used improperly does not mean it should not be used. In fact, the major medicolegal issue surrounding POCUS is failure to perform it in a timely fashion.⁷

LUNG AND PLEURAL ULTRASONOGRAPHY

Lung and pleural ultrasonography can narrow the broad differential diagnosis of respiratory distress (Table 2)⁸⁻¹¹ and facilitate prompt management.¹² In many hospitals, no radiologist is available to perform lung ultrasonography, making lung and pleural POCUS a critical skill for hospitalists. Training in lung and pleural POCUS is feasible with a simple curriculum consisting of didactics and limited supervised examinations.^{13,14}

Initial lung assessment

Lung assessment starts with identifying the pleural line, a shimmering hyperechoic structure between the ribs (Figure 1). Respirophasic sliding of the pleura gives a shimmering appearance, referred to as “lung sliding.”

The tissue-air interface in the subpleural region of aerated lung is a strong reflector. Ultrasound is repeatedly reflected between the pleura and the probe, leading to a reverberation artifact appearing as equidistant parallel echoic lines, known as A lines (Figure 1). An A-line pattern indicates normal lung, but it can also be seen with pneumothorax and in conditions with normally aerated pulmonary parenchyma, such as pulmonary embolism, chronic obstructive pulmonary disease, and asthma.¹⁵

Evaluation of pneumothorax

In pneumothorax, the air between the parietal and visceral pleurae prevents pleural contact, giving an A-line pattern without lung sliding. Absence of lung sliding has good sensitivity (> 95%) for pneumothorax but poor specificity (60%–99%).^{8,16} This pattern also occurs

The absence of lung sliding should prompt the search for ‘lung point,’ which is virtually pathognomonic for pneumothorax

TABLE 2

Meta-analyses evaluating pleural and lung ultrasonography

Diagnosis	Meta-analysis	No. of studies	No. of patients	Pooled sensitivity	95% confidence interval	Pooled specificity	95% confidence interval	Positive likelihood ratio	Negative likelihood ratio
Pleural effusion	Yousefifard et al, ¹¹ 2016	12	1,554	94%	88%–97%	98%	92%–100%	53.96	0.06
Acute cardiogenic pulmonary edema	Maw et al, ⁹ 2019	7	1,075	94.1%	81.3%–98.3%	92.4%	84.2%–96.4%	12.38	0.06
Pneumonia	Alzahrani et al, ¹⁰ 2017	20	2,513	85%	84%–87%	93%	92%–95%	12.14	0.16
Pneumo-thorax	Alrajab et al, ⁸ 2013 ^a	13	1,514	78.6%	68.1%–98.1%	98.4%	97.3%–99.5%	49.13	0.22

^a Included 1 study that used lung sliding sign alone, 12 studies that used lung sliding and comet tail signs, and 6 studies that included lung point in addition to the other 2 signs.

with pleural adhesions, apnea, pneumonia, and right mainstem bronchus intubation.^{16,17} The absence of lung sliding should prompt the search for “lung point,” ie, the transition point at the edge of the pneumothorax where lung sliding is seen in one part and no lung sliding is seen in the rest. Lung point is virtually pathognomonic for pneumothorax (Video 1).¹⁷

Unlike lung point, absent lung sliding is not specific for pneumothorax and should not by itself prompt tube thoracostomy in the absence of extenuating circumstances (eg, severe cardiorespiratory instability, high clinical suspicion).

Evaluation of alveolar-interstitial syndrome

The pathologies of alveolar-interstitial space are characterized by B lines, a sonographic pattern of vertically oriented, laser-like hyperechoic artefacts originating at the pleural interface, extending downwards, and moving synchronously with the pleura (Figure 2). One or 2 B lines are routinely seen; 3 or more in a single field of view is considered abnormal.^{18–20} Any condition that leads to thickening of subpleural interlobular septa generates B lines, the most common being pulmonary edema (cardiogenic or noncardiogenic in origin).

The sensitivity of B lines in identifying pulmonary edema is at least 90%,^{9,21,22} making POCUS an excellent tool to differentiate car-

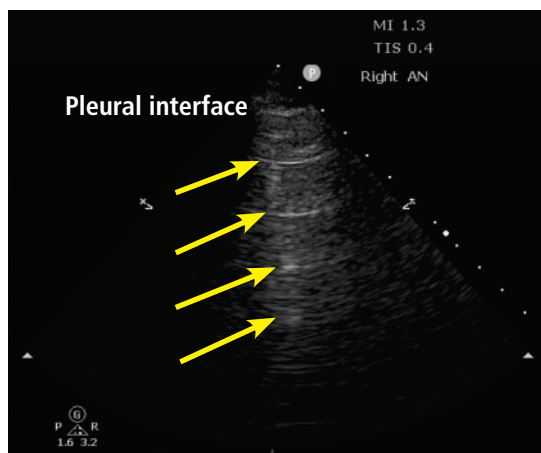
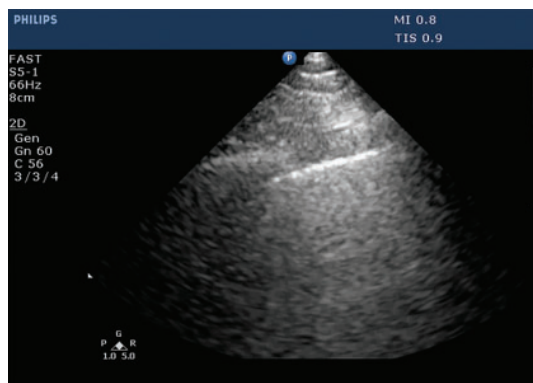


Figure 1. A lines. The A-line pattern occurs in normal lung and in pneumothorax. Ultrasound waves (arrows) reflect off the pleural interface repeatedly, producing repeated horizontal lines throughout the field.



Video 1. Lung point.

View videos for this article at ccjm.org

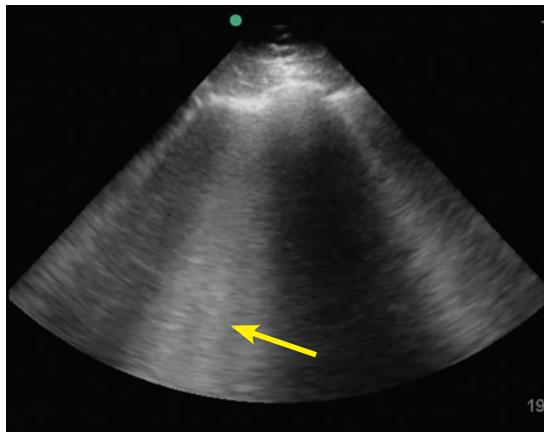


Figure 2. B lines. The B-line pattern occurs in the setting of interstitial thickening by any cause, including cardiogenic pulmonary edema, noncardiogenic pulmonary edema, interstitial fibrosis, and interstitial pneumonia/pneumonitis. It is analogous to ground-glass opacity on computed tomography. It is demonstrated by vertical lines resembling the tail of a comet and extending to the bottom of the screen. In this image, confluent B lines (arrow) indicate significant interstitial involvement.

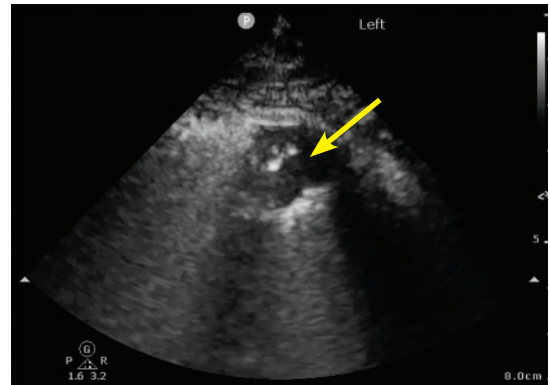


Figure 3. Small peripheral (subpleural) consolidation. This is demonstrated by a small area of lung parenchyma visualized directly beneath the pleura (arrow). This pattern is common in bacterial or viral pneumonia, including COVID-19 pneumonia.

Focused cardiac ultrasonography provides critical insight into hemodynamic status

diogenic pulmonary edema from exacerbation of chronic obstructive pulmonary disease. In addition, B lines may help guide diuresis and assess fluid tolerance.

B lines also occur in pneumonia, pulmonary fibrosis, acute respiratory distress syndrome, and pneumonitis of any etiology. Careful evaluation of the pattern of B-line distribution and the pleural line, along with clinical correlation, can help distinguish these different causes (Table 3).^{23–25}

The presence of B lines effectively rules out pneumothorax, as they are produced from subpleural lung units.¹⁷

Evaluation of consolidation

Ultrasound waves can traverse subpleural lung consolidation, resulting in the absence of A lines and a true 2-dimensional image of the consolidated lung (Figure 3). Almost all acute alveolar consolidations (98.5%) are found adjoining the visceral pleura, providing the necessary window for detection.²⁶

The finding of subpleural consolidation or focal B lines, or both, is suggestive of pneumonia. The sensitivity and specificity of lung

ultrasonography for diagnosing pneumonia is just 85% or more.¹⁰ Nonetheless, supportive clinical and laboratory data with the characteristic ultrasound patterns can substantiate a diagnosis of pneumonia.

Evaluation of pleural effusion

Portable chest radiography has a sensitivity of 60% for detecting pleural effusion²⁷; in contrast, lung ultrasonography is 94% sensitive and 98% specific.¹¹ Lung ultrasonography can also better characterize basal opacities by distinguishing consolidation from pleural effusion (Figure 4). It can also detail the features of pleural effusion, with simple effusion appearing anechoic, and complex effusions characterized by septations, loculations, and debris. The size of a pleural effusion can also be quantified using lung ultrasonography.²⁸

FOCUSED CARDIAC ULTRASONOGRAPHY

Focused cardiac ultrasonography (this term is preferred to “echocardiography” to highlight its focused nature) provides critical insight into hemodynamic status. It can be performed with excellent diagnostic accuracy for important cardiac abnormalities (Table 4).²⁹

Focused questions, including global assessment of left ventricular function, presence or absence of a pericardial effusion, assessment of right ventricular size and function, and estimation of right atrial pressure, can help nar-

TABLE 3

Characteristics of B lines based on etiology^a

	Cardiogenic pulmonary edema	Noncardiogenic diffuse pulmonary interstitial edema	Interstitial pneumonia or pneumonitis (bacterial, viral, or inflammatory)	Interstitial fibrosis
Distribution	Diffuse Usually bilateral and symmetric Predominant in dependent regions	Diffuse or patchy Often asymmetric	Focal or patchy Usually asymmetric	Diffuse or patchy Variable symmetry
Spared areas	Absent	Often present	Present	Often present
Number of B lines	Variable	Variable	Variable	Variable
Pleura	Smooth	Irregular	Irregular	Irregular
Subpleural consolidations	Absent	Present	Present	Typically absent
Reduced lung sliding	Absent	May be present	May be present	May be present
Pleural effusion	Often present	Typically absent	May be present	Typically absent

^aDefining the terminology: diffuse = present throughout; patchy = present in many areas throughout, absent in other areas throughout; focal = present in one region but not in others; spared areas = regions of lung with A-line pattern (amid a background of B-line pattern).

row a differential diagnosis and guide management in patients with cardiorespiratory distress.

Evaluating left ventricular function

Evaluation of left ventricular systolic function is one of the primary objectives of focused cardiac ultrasonography. As a general rule, multiple views should be obtained for appropriate interpretation. Although objective methods of left ventricular systolic evaluation are available and recommended, qualitative “eyeball estimation” is appropriate and feasible, with studies demonstrating high accuracy of visual estimation compared with recommended objective measures.^{30,31} Left ventricular systolic function can be qualitatively graded as severely reduced, moderately reduced, mildly reduced, normal, or hyperdynamic. Cardiology-performed echocardiography can be requested for further quantitative evaluation (Video 2, Video 3).

Evaluating right ventricular function

Better understanding of the importance of right ventricular function has led to including

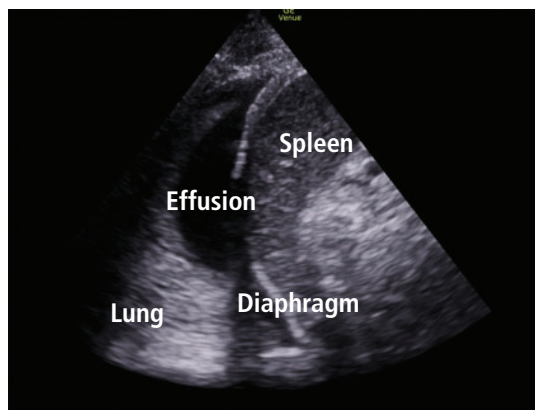


Figure 4. Pleural effusion and consolidation.

its evaluation in various protocols assessing shock and respiratory failure.³² Although objectively estimating right ventricular size and function is challenging, qualitative assessment can be made at the bedside by directly comparing the left and right ventricle.

Size. The right ventricle is normally less than two-thirds the size of the left. A right ventricle-to-left ventricle ratio of 1 or higher is associated with poor outcomes in pulmo-

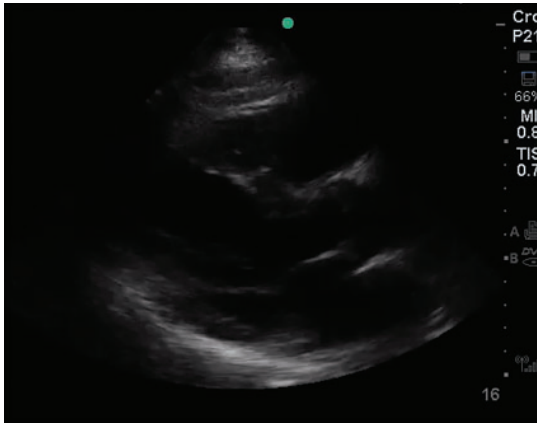Evaluating left ventricular systolic function is one of the primary objectives of focused cardiac ultrasonography

TABLE 4

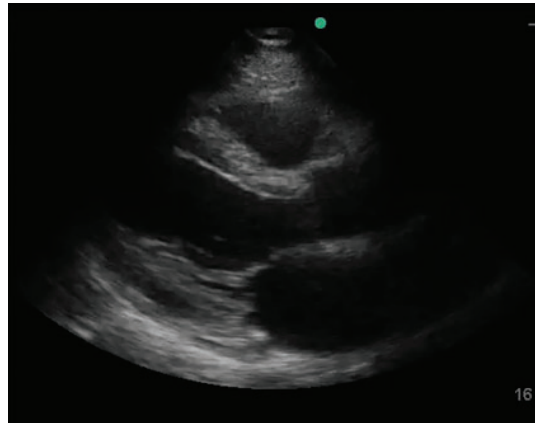
Focused cardiac ultrasonography: Basic views and key findings

Views	Probe position	Possible findings
<p>■ PLAX</p>	<p>Left 3rd to 5th intercostal space adjacent to the sternum, with probe marker pointing toward the right shoulder</p>	<p>Pericardial effusion Signs of tamponade Left ventricular size and systolic function Mitral and aortic valvular pathology Aortic root dissection</p>
<p>■ PSAX AV Level</p>	<p>From the PLAX view, the probe is rotated 90° clockwise. PSAX views are obtained by tilting the transducer from the base to the apex of the left ventricle.</p>	<p>Left ventricular systolic function Tricuspid, aortic, and mitral valvular pathology Interventricular septal deviation Wall-motion abnormalities</p>
<p>■ PSAX Papillary M</p>		
<p>■ Apical 4 Chamber</p>	<p>With the probe marker pointing toward the left, the probe is placed at the apex of the left ventricle. The apical impulse can be used as a guide.</p>	<p>Left ventricular size and function Right ventricular size and function Pericardial effusion and signs of tamponade Valvular pathology Interventricular septal deviation Wall-motion abnormalities</p>
<p>■ SC 4 Chamber</p>	<p>The probe is placed below the xiphoid process, with the marker pointing toward the left.</p> <p>From the subcostal long-axis view, the probe is rotated 90° counterclockwise and angulated slightly toward the left.</p>	<p>Pericardial effusion and signs of tamponade Inferior vena cava size and collapsibility</p>
<p>■ SC IVC</p>		

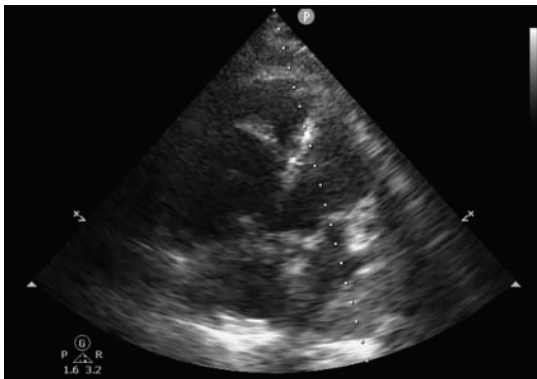
AV = aortic valve; IVC = inferior vena cava; LV = left ventricle; MV = mitral valve; PLAX = parasternal long axis; PSAX = parasternal short axis; RV = right ventricle; TV = tricuspid valve



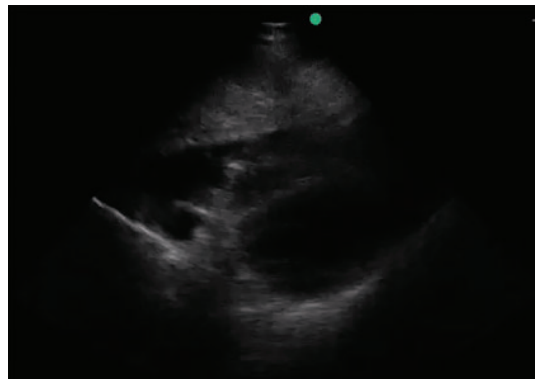
Video 2. Normal parasternal long axis view.



Video 3. Reduced ejection fraction.



Video 4. Dilated right ventricle.



Video 5. Pericardial effusion and tamponade.

B lines may help guide diuresis and assess fluid tolerance

nary hypertension, pulmonary embolism, and other critical conditions.

Septal kinetics. Assessing septal kinetics can also provide vital insights and help identify the cause of right ventricular dysfunction: septal deviation occurs toward the left ventricle in diastole with right ventricular volume overload, and during systole with right ventricular pressure overload.

Chronicity. It is important to distinguish acute from chronic right ventricular dysfunction, as their causes differ. Distinguishing them is challenging with focused cardiac ultrasonography, yet certain subtle findings can point to the cause.

Chronic dysfunction is seen in long-standing cases of pulmonary hypertension. It is associated with right ventricular hypertrophy with right ventricular free-wall thickness of more than 5 mm (**Video 4**).

Acute dysfunction raises concern for massive pulmonary embolism, acute respiratory

distress syndrome, and acute right ventricular infarction. In acute right ventricular dysfunction, particularly pulmonary embolism, the McConnell sign (ie, right ventricular free-wall akinesis with sparing of the apex) is just 70% sensitive and 33% specific for diagnosing acute pulmonary embolism (positive likelihood ratio [PLR] 1.04, negative likelihood ratio [NLR] 0.91).³³ Hence, pulmonary embolism cannot be definitively diagnosed with focused cardiac ultrasonography, with the notable exception of detecting a visible thrombus in the right heart (ie, a clot in transit).

Evaluating valvular abnormalities

Limited evaluation of the mitral, tricuspid, and aortic valves can be performed using standard views. With some experience, gross abnormalities that may significantly alter management (eg, flail leaflet, prolapse, large vegetation, chordae rupture) can be detected on visual examination and color Doppler. Dynamic left ventricular outflow tract obstruc-

TABLE 5

Estimates of central venous pressure based on inferior vena cava size and collapsibility

Inferior vena cava size	Percent collapse	Estimated central venous pressure
≤ 2.1 cm	> 50%	3 mm Hg
≤ 2.1 cm	< 50%	8 mm Hg
> 2.1 cm	> 50%	8 mm Hg
> 2.1 cm	< 50%	15 mm Hg

Based on reference 35.

tion due to systolic anterior motion of the mitral valve can be detected visually and by using motion mode (M mode). Although systolic anterior motion is classically seen with hypertrophic cardiomyopathy, it may also occur in other situations that lead to worsening hemodynamics (eg, sepsis, acute hemorrhage, dehydration). Systolic anterior motion may be associated with severe mitral regurgitation, which resolves with resolution of systolic anterior motion.

However, bedside echocardiography is limited for assessing valvular pathologies. A detailed assessment of valvular lesions (especially stenotic lesions) involves use of spectral Doppler in multiple views, which is not part of basic cardiac ultrasonography. Hence, a comprehensive echocardiographic examination should be considered for evaluating valvular abnormalities and pathology.³⁴

Estimating right atrial pressure

In spontaneously breathing patients, right atrial pressure can be estimated by measuring inferior vena cava size and collapsibility with deep inspiration or “sniff” (Table 5).³⁵ The influence of respiratory effort, intra-abdominal pressure, and positive-pressure ventilation may limit the accuracy of the measurement and should be considered. Additionally, the long-axis view of the inferior vena cava is prone to error due to off-plane assessment and respirophasic movement. This can be overcome by acquiring a short-axis (transverse) view.³⁶

Evaluating pericardial effusion and tamponade

Focused cardiac ultrasonography has excellent sensitivity (96%) and specificity (98%)

for detecting pericardial effusion (PLR 48, NLR 0.04)³⁷ and can trigger further consultation for evaluation of tamponade, if clinically suspected (Video 5, Table 4). Hemodynamic instability from cardiac tamponade results from increased pericardial pressure, impairing venous return. The rate of fluid accumulation plays a more prominent role than size in tamponade physiology. Thus, a large volume of pericardial effusion can accumulate over time without impairing hemodynamics, while a smaller pericardial effusion or hemorrhage in the setting of trauma or postprocedure can lead to the need to diligently inspect echocardiographic signs of tamponade.

A plethoric inferior vena cava from impaired filling is highly sensitive (92%) but not specific for cardiac tamponade. Right atrial collapse for more than one-third of the cardiac cycle is highly sensitive and specific for diagnosing tamponade, followed by right ventricular collapse during diastole.³⁸ Absence of chamber collapse has a negative predictive value of 90%. Assessing for tamponade can be difficult, and M mode may help identify chamber collapse. Concerning or indeterminate findings for tamponade should prompt urgent expert consultation or a confirmatory echocardiogram, or both.

POCUS has been shown to reduce time to pericardiocentesis and is recommended to guide drainage of effusion.³⁹

Common pitfalls of focused cardiac ultrasonography

Focused cardiac ultrasonography is prone to the following common issues:

Not obtaining a complete echocardiogram when needed. A focused study serves a

Lung ultrasonography is 94% sensitive and 98% specific for detecting pleural effusion

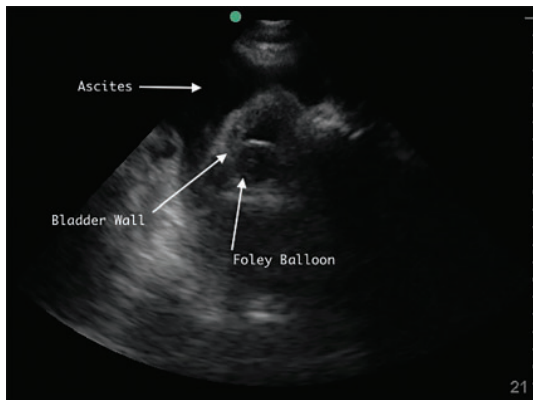


Figure 5. Right lower quadrant with large ascites fluid pocket; Foley catheter in bladder.

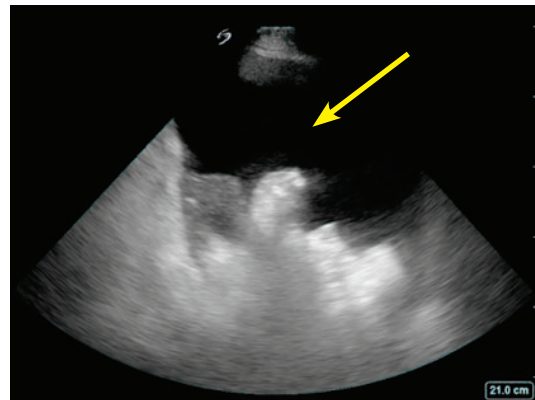


Figure 6. Ascites pocket.

different purpose from a complete study and should not replace one. Hence, a “normal” focused cardiac ultrasonographic evaluation does not obviate the need to order a complete transthoracic echocardiogram that is clinically indicated.

Over-relying on POCUS to manage volume. POCUS findings are useful as part of volume status assessment, but a single POCUS finding in isolation should not be used to determine volume management (eg, giving fluids for an apparently “collapsed” inferior vena cava). Findings are prone to variability and must be integrated into overall assessment, not used in isolation.

Delaying POCUS during shock. Focused cardiac ultrasonography should be performed promptly in a patient with shock. Not doing so may lead to an important missed diagnosis, such as pericardial tamponade, ventricular dysfunction, or valvular abnormality.

■ ABDOMINAL ULTRASONOGRAPHY

Evaluation of ascites and hemoperitoneum

Evaluating thoracoabdominal trauma is often a diagnostic challenge, prompting clinicians to depend on ancillary tests to detect potentially life-threatening internal injuries. Ultrasonographic evaluation of free fluid in the abdomen has been extensively studied in trauma literature for detecting hemoperitoneum. Today, ultrasonography has virtually replaced diagnostic peritoneal lavage as a primary, bedside imaging method for trauma patients.⁴⁰ Numerous studies have found that examinations performed and interpreted by

treating physicians are reliably accurate compared with those read by radiologists.⁴¹

POCUS can also help hospitalists detect ascites. It is more sensitive and specific than physical examination and can guide the decision to perform paracentesis (**Figure 5, Figure 6**).⁴²

Evaluation of kidney and bladder

Hydronephrosis, a commonly encountered and often reversible cause of acute kidney injury, can be detected with high sensitivity and specificity by a bedside clinician using POCUS (**Figure 7**).⁴³ Hydronephrosis results from urinary flow obstruction, which can be internal (eg, from ureteral calculus or a mass) or external (eg, from ureteral compression from structures such as an enlarged abdominal aortic aneurysm, an advanced pregnancy, or a pelvic mass). Evaluation for hydronephrosis can be useful in cases in which urinary obstruction is considered. This may be particularly important in patients with acute pyelonephritis. However, mimics of hydronephrosis include prominent renal pyramids, prominent renal vasculature, and parapelvic cysts.

Distal obstruction (eg, prostatic hypertrophy) usually results in bilateral hydronephrosis, so it is important to scan both kidneys.

A study found more than 90% sensitivity and specificity for detecting hydronephrosis by POCUS performed by internal medicine residents given 5 hours of training compared with comprehensive radiologic ultrasonography.⁴⁴

POCUS is also helpful in acute pyelonephritis to evaluate for obstruction. Detecting large obstructive calculi would prompt urgent

Hydronephrosis can be detected with high sensitivity and specificity with POCUS

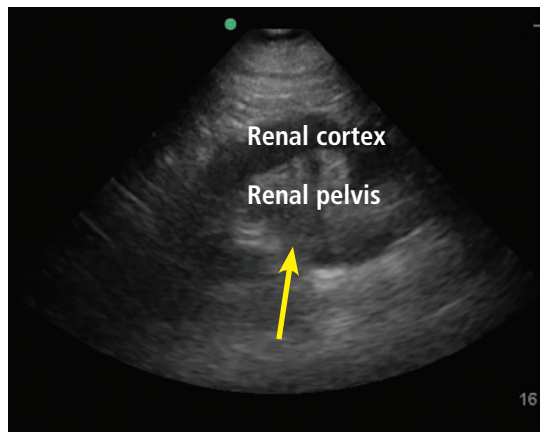


Figure 7. Hydronephrosis. Hypoechoic (dark) fluid (arrow) is shown extending into the renal pelvis.

urologic consultation.

A distended bladder, being a large fluid-filled structure, is easily visualized by ultrasonography and can be distinguished from ascitic fluid. POCUS can be used to estimate bladder volume and confirm proper placement of a urinary catheter by visualizing a Foley balloon inside the bladder (Figure 5). This application may be particularly useful in a patient with obesity or ascites, which can make physical examination or bladder scanner determinations inaccurate. In patients without a urinary catheter, bladder volume estimation should be performed post-void.

Ultrasound evaluation of the biliary system

Gallstones appear by ultrasonography as round hyperechoic structures in the gallbladder or bile ducts, with posterior acoustic shadowing. POCUS has demonstrated excellent sensitivity (89.8%) and specificity (88.0%) for detecting cholelithiasis (PLR 7.48, NLR 0.12).⁴⁵ Findings suggestive of acute cholecystitis include gallstones, pericholecystic fluid, gallbladder wall thickening, and sonographic Murphy sign (ie, abdominal pain elicited by probe pressure), all of which can be assessed at the bedside with good specificity (Figure 8).⁴⁶

The common bile duct can also be measured by POCUS, although it is technically challenging, especially for a novice user.⁴⁷ Requesting a formal ultrasonographic study is prudent to obtain this information.

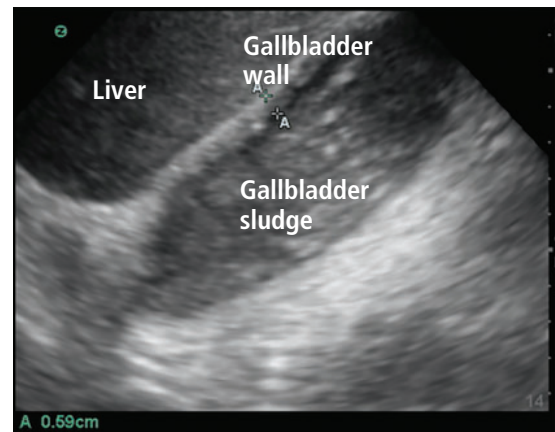

Figure 8. Gallbladder containing sludge, with a thickened anterior wall, in a patient with acute cholecystitis.

EVALUATION OF LOWER-EXTREMITY DEEP VEIN THROMBOSIS

Although complete duplex ultrasonography is the standard radiological study traditionally performed to evaluate for deep vein thrombosis (DVT), point-of-care compression ultrasonography can be performed rapidly with high diagnostic accuracy after limited training (Figure 9).⁴⁸ A multicenter study of hospitalist-performed compression ultrasonography found a sensitivity of 100% and specificity of 96% for identifying lower extremity DVT, reducing the time to diagnosis by nearly 5 hours compared with corresponding vascular studies interpreted by radiologists.⁴⁹ Meta-analyses have also reported sensitivity and specificity higher than 90% (Table 6).^{50–52} However, inadequate compression, lymph nodes, Baker cysts, and superficial venous thrombosis may be mistaken for a DVT.

A focused DVT study is performed using a high-frequency (5–12 MHz) linear probe with compression of the vein at multiple sites, traditionally using a 2-point (common femoral vein and popliteal vein) or 3-point (same, plus superficial femoral vein) method. The 3-point examination demonstrated higher sensitivity (91% vs 83%) and similar specificity (96%) to the 2-point examination, but it still can miss 5% of isolated femoral vein DVTs.⁵³ An extended compression examination employing compressing the femoral vein every 2 to 3 cm until it dives into the adductor canal and popliteal vein along its course is more com-

Findings that suggest acute cholecystitis can be assessed with POCUS with good specificity

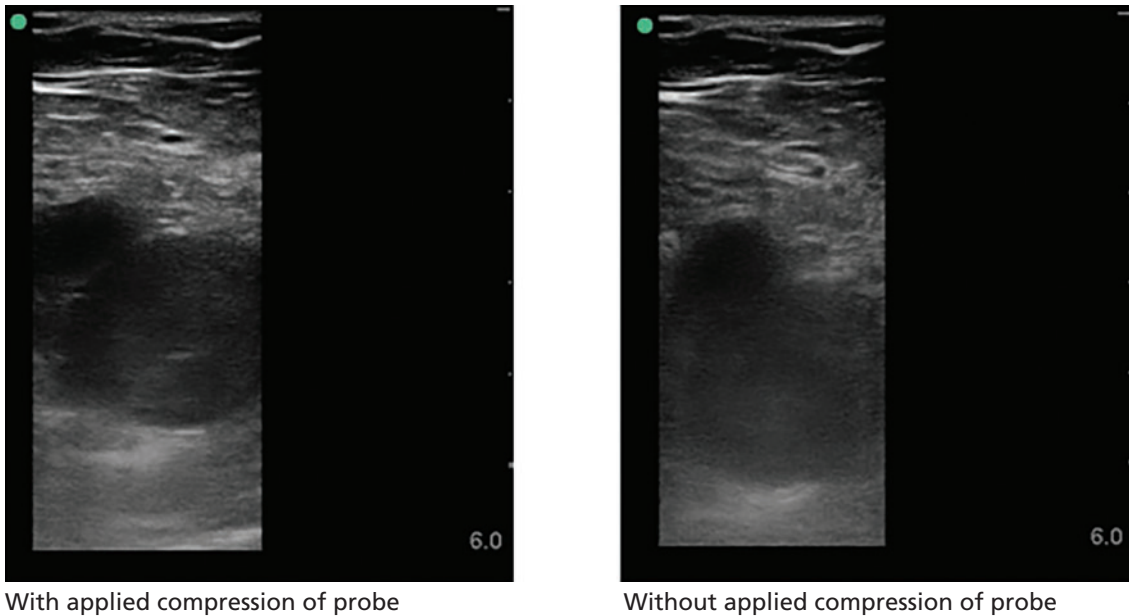


Figure 9. Right common femoral vein deep vein thrombosis. The left image shows lack of compression of the vein with applied compression of the probe. The right image shows vein without compression.

prehensive and is currently the recommended method.³

Duplication of the venous system in the lower extremity is common, and the presence of a DVT in duplicated systems could easily be missed.⁵⁴ A positive POCUS examination may prompt early initiation of anticoagulation and ordering of confirmatory imaging; a negative POCUS test in a patient with high pretest probability needs a comprehensive vascular study. The negative predictive value for a POCUS DVT study is not sufficient to effectively rule out DVT in such patients.

■ EVALUATING SKIN AND SOFT-TISSUE INFECTIONS

The major role of POCUS in evaluating skin and soft-tissue infection is to detect abscess formation in the soft tissue. It has been found to change management in more than half of patients presenting with a skin or soft-tissue infection.⁵⁵

The cobblestone appearance of cellulitis (**Figure 10**) is nonspecific and can be seen in any cause of subcutaneous edema, while ultrasonography is 98% sensitive and 88% specific for abscess detection (PLR 8.17, NLR 0.02).⁵⁶

The appearance of abscesses ranges from anechoic to hyperechoic and may demonstrate posterior acoustic enhancement.

Color Doppler is highly informative, as abscess cavities do not have internal Doppler flow. The presence of flow within the cavity may suggest a vascular structure such as a pseudoaneurysm. Air within the cavity, suggestive of high-grade infection, can be easily detected with ultrasonography.

Ultrasonography may also help diagnose necrotizing fasciitis by detecting fascial and subcutaneous thickening, abnormal fluid accumulation in the deep fascia layer, and subcutaneous air. However, ultrasonography should not be used to rule out the diagnosis of necrotizing fasciitis.

■ ULTRASONOGRAPHY FOR PROCEDURAL GUIDANCE

Numerous procedures common to hospital medicine practice may be performed more safely and effectively with ultrasonography. The Society of Hospital Medicine has published recommendations for the use of ultrasonography in common hospital medicine procedures, including abdominal paracentesis,⁴² thoracentesis,⁵⁷ lumbar puncture,⁵⁸ and

The major role of POCUS in evaluating skin and soft-tissue infection is to detect abscess formation in soft tissue

TABLE 6

Meta-analyses evaluating point-of-care ultrasonography for diagnosing deep vein thrombosis

Meta-analysis	No. of studies	No. of patients	Pooled sensitivity	95% confidence interval	Pooled specificity	95% confidence interval	Positive likelihood ratio	Negative likelihood ratio
Burnside et al, ⁵⁰ 2008	6	936	95%	87%–99%	96%	87%–99%	23.75	0.05
Pomero et al, ⁵¹ 2013	16	2,379	96.1%	90.6%–98.5%	96.8%	94.6%–98.1%	30.03	0.04
West et al, ⁵² 2015	13	1,806	96.5%	90.1%–98.8%	96.8%	94.7%–98.0%	30.16	0.04

Many predict that POCUS will be the standard of care in the near future

venous access,⁵⁹ as well as for procedural credentialing.⁶⁰

Procedures may be “ultrasound-assisted” or “static” (ie, ultrasonography is used for site selection, then the procedure is performed without ultrasonography) vs “ultrasound-guided” or “dynamic” (ie, the procedure is performed with live ultrasonographic guidance, with the ultrasound probe in one hand and a needle in the other).

Central venous catheter insertion

For central venous catheter insertion, ultrasonography reduces time to completion and decrease failed attempts, with fewer complications like pneumothorax and arterial punctures. It also aids in preprocedural detection of stenosis and thrombosis of the target vein, and it is currently the standard of care for upper-extremity central venous catheter insertion.⁶¹ Nonetheless, this procedure remains highly user-dependent, and adequate training is critical.⁶²

Peripheral intravenous catheter insertion

Ultrasonography is increasingly used to guide peripheral intravenous catheter insertion. In addition to increasing patient satisfaction, it has demonstrated a higher success rate, particularly in patients with difficult access, reducing the need for a central venous catheter. Ultrasonography can also be used to confirm the correct placement by visualizing the catheter in the vein or detecting bubbles with saline flush.⁶³

Abdominal paracentesis

Ultrasonographic guidance of paracentesis has been found to have a 95% success rate compared with 61% using the traditional landmark-based method.⁶⁴ Unsurprisingly, paracentesis was successfully completed with ultrasonogra-

phy in 87% of the patients for whom the landmark method failed. In a large observational database study of 70,000 patients undergoing paracentesis, ultrasonographic guidance significantly reduced bleeding complications.^{65,66}

In addition, a linear probe can help identify underlying vasculature, including the inferior epigastric artery, further minimizing major bleeding risk.

Thoracentesis

Ultrasonography has also demonstrated a higher rate of success and fewer complications for thoracentesis. In a meta-analysis of 24 studies with 6,605 thoracentesis procedures, ultrasonography significantly reduced pneumothorax compared with the landmark technique, even with inexperienced operators.⁶⁷ The procedure can be performed using static or dynamic ultrasonographic guidance. If static technique is used, the patient position needs to be maintained after marking the spot.

Evaluation of normal lung sliding preprocedure and postprocedure obviates the need for chest radiographs to rule out pneumothorax.⁵⁷

Common pitfalls

Ultrasound gel can prevent effective preprocedural aseptic skin preparation and postprocedural dressing adherence. Gel should dry before cleaning the skin or applying a dressing.

In addition, use of ultrasonography may sometimes lead to failure to look at anatomical landmarks, leading to performing a procedure at a nonideal site. Users should be mindful of anatomic landmarks in addition to sonographic features.

CONCLUSION

The role of bedside ultrasonography has undergone a paradigm shift, with a variety of applications being explored. This shift has been driven by the realization that performance of POCUS is a readily achievable skill and is rewarding in daily practice. It is no surprise that many predict that it will be the standard of care in the near future. Hospitalists are at the forefront of patient care and should be cognizant of the many benefits of POCUS. We hope that wider utilization of ultrasonography at the bedside can improve medical decision-making, translating to better patient care. ■

DISCLOSURES

The authors report no relevant financial relationships which, in the context of their contributions, could be perceived as a potential conflict of interest.

REFERENCES

- Howard ZD, Noble VE, Marill KA, et al. Bedside ultrasound maximizes patient satisfaction. *J Emerg Med* 2014; 46(1):46–53. doi:10.1016/j.jemermed.2013.05.044
- Fox S, Dugar S. Point-of-care ultrasound and COVID-19. *Cleve Clin J Med* 2020 May 14. doi:10.3949/ccjm.87a.ccc019
- Soni NJ, Schnobrich D, Mathews BK, et al. Point-of-care ultrasound for hospitalists: a position statement of the Society of Hospital Medicine. *J Hosp Med* 2019; 14:E1–E6. doi:10.12788/jhm.3079
- Soni NJ, Tierney DM, Jensen TP, Lucas BP. Certification of point-of-care ultrasound competency. *J Hosp Med* 2017; 12(9):775–776. doi:10.12788/jhm.2812
- American College of Physicians. ACP statement in support of point-of-care ultrasound in internal medicine. Accessed April 20, 2021. <https://www.acponline.org/meetings-courses/focused-topics/point-of-care-ultrasound-pocus-for-internal-medicine/acp-statement-in-support-of-point-of-care-ultrasound-in-internal-medicine>.
- PSNet. "The ultrasound looked fine": point-of-care ultrasound and patient safety. Accessed April 20, 2021. <https://www.psnet.ahrq.gov/web-mm/ultrasound-looked-fine-point-care-ultrasound-and-patient-safety>.
- Blaivas M, Pawl R. Analysis of lawsuits filed against emergency physicians for point-of-care emergency ultrasound examination performance and interpretation over a 20-year period. *Am J Emerg Med* 2012; 30(2):338–341. doi:10.1016/j.ajem.2010.12.016
- Alrajab S, Youssef AM, Akkus NI, Caldito G. Pleural ultrasonography versus chest radiography for the diagnosis of pneumothorax: review of the literature and meta-analysis. *Crit Care* 2013; 17(5):R208. doi:10.1186/cc13016
- Maw AM, Hassanin A, Ho PM, et al. Diagnostic accuracy of point-of-care lung ultrasonography and chest radiography in adults with symptoms suggestive of acute decompensated heart failure: a systematic review and meta-analysis. *JAMA Netw Open* 2019; 2(3):e190703. doi:10.1001/jamanetworkopen.2019.0703
- Alzahrani SA, Al-Salamah MA, Al-Madani WH, Elbarbary MA. Systematic review and meta-analysis for the use of ultrasound versus radiology in diagnosing of pneumonia. *Crit Ultrasound J* 2017; 9(1):6. doi:10.1186/s13089-017-0059-y
- Yousefifard M, Baikpour M, Ghelichkhani P, et al. Screening performance characteristic of ultrasonography and radiography in detection of pleural effusion: a meta-analysis. *Emerg (Tehran)* 2016; 4(1):1–10. PMID:26862542
- Laursen CB, Sloth E, Lassen AT, et al. Point-of-care ultrasonography in patients admitted with respiratory symptoms: a single-blind, randomised controlled trial. *Lancet Respir Med* 2014; 2(8):638–646. doi:10.1016/S2213-2600(14)70135-3
- Rouby JJ, Arbelot C, Gao Y, et al. Training for lung ultrasound score measurement in critically ill patients. *Am J Respir Crit Care Med* 2018; 198(3):398–401. doi:10.1164/rccm.201802-0227LE
- Pivetta E, Goffi A, Lupia E, et al. Lung ultrasound-implemented diagnosis of acute decompensated heart failure in the ED: a SIMEU multicenter study. *Chest* 2015; 148(1):202–210. doi:10.1378/chest.14-2608
- Lichtenstein DA. *Whole Body Ultrasonography in the Critically Ill*. Berlin Heidelberg: Springer-Verlag; 2010.
- Husain LF, Hagopian L, Wayman D, Baker WE, Carmody KA. Sonographic diagnosis of pneumothorax. *J Emerg Trauma Shock* 2012; 5(1):76–81. doi:10.4103/0974-2700.93116
- Lichtenstein D, Mezière G, Biderman P, Gepner A. The "lung point": an ultrasound sign specific to pneumothorax. *Intensive Care Med* 2000; 26(10):1434–1440. doi:10.1007/s001340000627
- Lichtenstein D, Mezière G. A lung ultrasound sign allowing bedside distinction between pulmonary edema and COPD: the comet-tail artifact. *Intensive Care Med* 1998; 24(12):1331–1334. doi:10.1007/s001340050771
- Soldati G, Copetti R, Sher S. Sonographic interstitial syndrome: the sound of lung water. *J Ultrasound Med* 2009; 28(2):163–174. doi:10.7863/jum.2009.28.2.163
- Volpicelli G, Mussa A, Garofalo G, et al. Bedside lung ultrasound in the assessment of alveolar-interstitial syndrome. *Am J Emerg Med* 2006; 24(6):689–696. doi:10.1016/j.ajem.2006.02.013
- Wang Y, Shen Z, Lu X, Zhen Y, Li H. Sensitivity and specificity of ultrasound for the diagnosis of acute pulmonary edema: a systematic review and meta-analysis. *Med Ultrason* 2018; 1(1):32–36. doi:10.11152/mu-1223
- Prosen G, Klemen P, Štrnad M, Grmec S. Combination of lung ultrasound (a comet-tail sign) and N-terminal pro-brain natriuretic peptide in differentiating acute heart failure from chronic obstructive pulmonary disease and asthma as cause of acute dyspnea in prehospital emergency setting. *Crit Care* 2011; 15(2):R114. doi:10.1186/cc10140

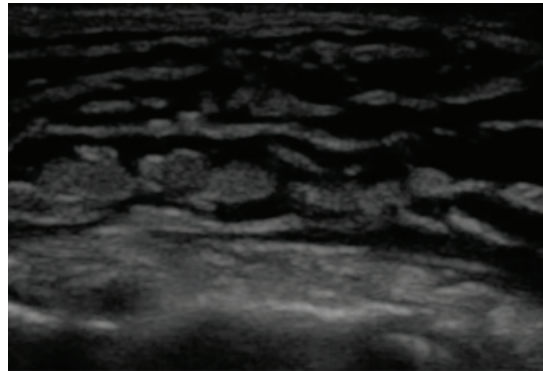


Figure 10. On ultrasonography, subcutaneous fluid is demonstrated as hypoechoic or anechoic (dark) layering within islands of subcutaneous tissue (gray). This occurs in any process leading to fluid within the subcutaneous tissue, including cellulitis and hydrostatic edema.

23. Xie HQ, Zhang WW, Sun S, et al. A simplified lung ultrasound for the diagnosis of interstitial lung disease in connective tissue disease: a meta-analysis. *Arthritis Res Ther* 2019; 21(1):93. doi:10.1186/s13075-019-1888-9
24. Lo Giudice V, Bruni A, Corcioni E, Corcioni B. Ultrasound in the evaluation of interstitial pneumonia. *J Ultrasound* 2008; 11(1):30–38. doi:10.1016/j.jus.2007.10.002
25. Dietrich CF, Mathis G, Blaivas M, et al. Lung B-line artefacts and their use. *J Thorac Dis* 2016; 8(6):1356–1365. doi:10.21037/jtd.2016.04.55
26. Lichtenstein DA, Lascols N, Mezière G, Gepner A. Ultrasound diagnosis of alveolar consolidation in the critically ill. *Intensive Care Med* 2004; 30(2):276–281. doi:10.1007/s00134-003-2075-6
27. Kitazono MT, Lau CT, Parada AN, Renjen P, Miller WT Jr. Differentiation of pleural effusions from parenchymal opacities: accuracy of bedside chest radiography. *AJR Am J Roentgenol* 2010; 194(2):407–412. doi:10.2214/AJR.09.2950
28. Ibitoye BO, Idowu BM, Ogunrombi AB, Afolabi BI. Ultrasonographic quantification of pleural effusion: comparison of four formulae. *Ultrasonography* 2018; 37(3):254–260. doi:10.14366/usg.17050
29. Lucas BP, Candotti C, Margeta B, et al. Diagnostic accuracy of hospitalist-performed hand-carried ultrasound echocardiography after a brief training program. *J Hosp Med* 2009; 4(6):340–349. doi:10.1002/jhm.438
30. Gudmundsson P, Rydberg E, Winter R, Willenheimer R. Visually estimated left ventricular ejection fraction by echocardiography is closely correlated with formal quantitative methods. *Int J Cardiol* 2005; 101(2):209–212. doi:10.1016/j.ijcard.2004.03.027
31. Melamed R, Sprengle MD, Ulstad VK, Herzog CA, Leatherman JW. Assessment of left ventricular function by intensivists using handheld echocardiography. *Chest* 2009; 135(6):1416–1420. doi:10.1378/chest.08-2440
32. Breittkreutz R, Price S, Steiger HV, et al. Focused echocardiographic evaluation in life support and periresuscitation of emergency patients: a prospective trial. *Resuscitation* 2010; 81(11):1527–1533. doi:10.1016/j.resuscitation.2010.07.013
33. Casazza F, Bongarzone A, Capozzi A, Agostoni O. Regional right ventricular dysfunction in acute pulmonary embolism and right ventricular infarction. *Eur J Echocardiogr* 2005; 6(1):11–14. doi:10.1016/j.euje.2004.06.002
34. Chamsi-Pasha MA, Sengupta PP, Zoghbi WA. Handheld echocardiography: current state and future perspectives. *Circulation* 2017; 136(22):2178–2188. doi:10.1161/CIRCULATIONAHA.117.026622
35. Rudski LG, Lai WW, Afilalo J, et al. Guidelines for the echocardiographic assessment of the right heart in adults: a report from the American Society of Echocardiography endorsed by the European Association of Echocardiography, a registered branch of the European Society of Cardiology, and the Canadian Society of Echocardiography. *J Am Soc Echocardiogr* 2010; 23(7):685–788. doi:10.1016/j.echo.2010.05.010
36. Schmidt GA. POINT: should acute fluid resuscitation be guided primarily by inferior vena cava ultrasound for patients in shock? Yes. *Chest* 2017; 151(3):531–532. doi:10.1016/j.chest.2016.11.021
37. Mandavia DP, Hoffner RJ, Mahaney K, Henderson SO. Bedside echocardiography by emergency physicians. *Ann Emerg Med* 2001; 38(4):377–382. doi:10.1067/mem.2001.118224
38. Klein AL, Abbara S, Agler DA, et al. American Society of Echocardiography clinical recommendations for multimodality cardiovascular imaging of patients with pericardial disease: endorsed by the Society for Cardiovascular Magnetic Resonance and Society of Cardiovascular Computed Tomography. *J Am Soc Echocardiogr* 2013; 26(9):965–1012.e15. doi:10.1016/j.echo.2013.06.023
39. Alpert EA, Amit U, Guranda L, Mahagna R, Grossman SA, Bentancur A. Emergency department point-of-care ultrasonography improves time to pericardiocentesis for clinically significant effusions. *Clin Exp Emerg Med* 2017; 4(3):128–132. doi:10.15441/ceem.16.169
40. Savatmongkorngul S, Wongwaisayawan S, Kaewlai R. Focused assessment with sonography for trauma: current perspectives. *Open Access Emerg Med* 2017; 9:57–62. doi:10.2147/OAEM.S120145
41. Bhoi S, Sinha TP, Ramchandani R, Kurrey L, Galwankar S. To determine the accuracy of focused assessment with sonography for trauma done by nonradiologists and its comparative analysis with radiologists in emergency department of a level 1 trauma center of India. *J Emerg Trauma Shock* 2013; 6(1):42–46. doi:10.4103/0974-2700.106324
42. Cho J, Jensen TP, Reiersen K, et al. Recommendations on the use of ultrasound guidance for adult abdominal paracentesis: a position statement of the Society of Hospital Medicine. *J Hosp Med* 2019; 14:E7–E15. doi:10.12788/jhm.3095
43. Wong C, Teitge B, Ross M, Young P, Robertson HL, Lang E. The accuracy and prognostic value of point-of-care ultrasound for nephrolithiasis in the emergency department: a systematic review and meta-analysis. *Acad Emerg Med* 2018; 25(6):684–698. doi:10.1111/acem.13388
44. Caronia J, Panagopoulos G, Devita M, et al. Focused renal sonography performed and interpreted by internal medicine residents. *J Ultrasound Med* 2013; 32(11):2007–2012. doi:10.7863/ultra.32.11.2007
45. Ross M, Brown M, McLaughlin K, et al. Emergency physician-performed ultrasound to diagnose cholelithiasis: a systematic review. *Acad Emerg Med* 2011; 18(3):227–235. doi:10.1111/j.1553-2712.2011.01012.x
46. Hilsden R, Leeper R, Koichopolos J, et al. Point-of-care biliary ultrasound in the emergency department (BUSED): implications for surgical referral and emergency department wait times. *Trauma Surg Acute Care Open* 2018; 3(1):e000164. doi:10.1136/tsaco-2018-000164
47. Lahham S, Becker BA, Gari A, et al. Utility of common bile duct measurement in ED point of care ultrasound: a prospective study. *Am J Emerg Med* 2018; 36(6):962–966. doi:10.1016/j.ajem.2017.10.064
48. Kory PD, Pellecchia CM, Shiloh AL, Mayo PH, DiBello C, Koenig S. Accuracy of ultrasonography performed by critical care physicians for the diagnosis of DVT. *Chest* 2011; 139(3):538–542. doi:10.1378/chest.10-1479
49. Fischer EA, Kinnear B, Sall D, et al. Hospitalist-operated compression ultrasonography: a point-of-care ultrasound study (HOCUS-POCUS). *J Gen Intern Med* 2019; 34(10):2062–2067. doi:10.1007/s11606-019-05120-5
50. Burnside PR, Brown MD, Kline JA. Systematic review of emergency physician-performed ultrasonography for lower-extremity deep vein thrombosis. *Acad Emerg Med* 2008; 15(6):493–498. doi:10.1111/j.1553-2712.2008.00101.x
51. Pomeroy F, Dentali F, Borretta V, et al. Accuracy of emergency physician-performed ultrasonography in the diagnosis of deep-vein thrombosis: a systematic review and meta-analysis. *Thromb Haemost* 2013; 109(1):137–145. doi:10.1160/TH12-07-0473
52. West JR, Shannon AW, Chilstrom ML. What is the accuracy of emergency physician-performed ultrasonography for deep venous thrombosis? *Ann Emerg Med* 2015; 65(6):699–701. doi:10.1016/j.annemergmed.2014.06.025
53. Adhikari S, Zeger W, Thom C, Fields JM. Isolated deep venous thrombosis: implications for 2-point compression ultrasonography of the lower extremity. *Ann Emerg Med* 2015; 66(3):262–266. doi:10.1016/j.annemergmed.2014.10.032
54. Zitek T, Baydoun J, Yopez S, Forred W, Slattery DE. Mistakes and pitfalls associated with two-point compression ultrasound for deep vein thrombosis. *West J Emerg Med* 2016; 17(2):201–208. doi:10.5811/westjem.2016.1.29335
55. Tayal VS, Hasan N, Norton HJ, Tomaszewski CA. The effect of soft-tissue ultrasound on the management of cellulitis in the emergency department. *Acad Emerg Med* 2006; 13(4):384–388. doi:10.1197/j.aem.2005.11.074
56. Squire BT, Fox JC, Anderson C. ABSCESS: applied bedside sonography for convenient evaluation of superficial soft tissue infections. *Acad Emerg Med* 2005; 12(7):601–606. doi:10.1197/j.aem.2005.01.016
57. Dancel R, Schnobrich D, Puri N, et al. Recommendations on the use of ultrasound guidance for adult thoracentesis: a position statement of the Society of Hospital Medicine. *J Hosp Med* 2018; 13(2):126–135. doi:10.12788/jhm.2940

58. **Soni NJ, Franco-Sadud R, Kobaidze K, et al.** Recommendations on the use of ultrasound guidance for adult lumbar puncture: a position statement of the Society of Hospital Medicine. *J Hosp Med* 2019; 14(10):591–601. doi:10.12788/jhm.3197
59. **Franco-Sadud R, Schnobrich D, Mathews BK, et al.** Recommendations on the use of ultrasound guidance for central and peripheral vascular access in adults: a position statement of the Society of Hospital Medicine. *J Hosp Med* 2019; 14:E1–E22. doi:10.12788/jhm.3287
60. **Lucas BP, Tierney DM, Jensen TP, et al.** Credentialing of hospitalists in ultrasound-guided bedside procedures: a position statement of the Society of Hospital Medicine. *J Hosp Med* 2018; 13(2):117–125. doi:10.12788/jhm.2917
61. **Lalu MM, Fayad A, Ahmed O, et al.** Ultrasound-guided subclavian vein catheterization: a systematic review and meta-analysis. *Crit Care Med* 2015; 43(7):1498–1507. doi:10.1097/CCM.0000000000000973
62. **Blaivas M, Adhikari S.** An unseen danger: frequency of posterior vessel wall penetration by needles during attempts to place internal jugular vein central catheters using ultrasound guidance. *Crit Care Med* 2009; 37(8):2345–2359. doi:10.1097/CCM.0b013e3181a067d4
63. **Gottlieb M, Sundaram T, Holladay D, Nakitende D.** Ultrasound-guided peripheral intravenous line placement: a narrative review of evidence-based best practices. *West J Emerg Med* 2017; 18(6):1047–1054. doi:10.5811/westjem.2017.7.34610
64. **Nazeer SR, Dewbre H, Miller AH.** Ultrasound-assisted paracentesis performed by emergency physicians vs the traditional technique: a prospective, randomized study. *Am J Emerg Med* 2005; 23(3):363–367. doi:10.1016/j.ajem.2004.11.001
65. **Patel PA, Ernst FR, Gunnarsson CL.** Evaluation of hospital complications and costs associated with using ultrasound guidance during abdominal paracentesis procedures. *J Med Econ* 2012; 15(1):1–7. doi:10.3111/13696998.2011.628723
66. **Mercaldi CJ, Lanes SF.** Ultrasound guidance decreases complications and improves the cost of care among patients undergoing thoracentesis and paracentesis. *Chest* 2013; 143(2):532–538. doi:10.1378/chest.12-0447
67. **Gordon CE, Feller-Kopman D, Balk EM, Smetana GW.** Pneumothorax following thoracentesis: a systematic review and meta-analysis. *Arch Intern Med* 2010; 170(4):332–339. doi:10.1001/archinternmed.2009.548

Address: Guramrinder Singh Thind, MD, Department of Critical Care Medicine, A90, Respiratory Institute, Cleveland Clinic, 9500 Euclid Avenue, Cleveland, OH 44195; thindg@ccf.org